



<https://doi.org/10.15446/cr.v3n2.60058>

AGENESIS OF THE GALLBLADDER AND CHOLEDOCHOLITHIASIS. CASE REPORT

Keywords: Gallbladder, abnormalities; Choledocholithiasis; Common bile duct diseases; Laparoscopy; CPRE (MeSH).

Palabras clave: Vesícula biliar, Anomalías; Coledocolitiasis; Conductos biliares, anomalías; Laparoscopia; ERCP (DeCS).

Daniel Rodrigo Riaño Pinto

Departamento de Cirugía
Facultad de Medicina
Universidad Nacional de Colombia
Sede Bogotá – Colombia

Corresponding author:

Daniel Rodrigo Riaño Pinto
Department of Surgery - Faculty of Medicine -
Universidad Nacional de Colombia
Bogotá - Colombia.
Email: drrianop@unal.edu.co

ABSTRACT

Introduction. The most frequent elective surgery in General Surgery is the gallbladder surgery (cholecystectomy) in General Surgery in adults. There are many abnormalities of the gallbladder and the common bile duct. The most uncommon case is gallbladder agenesis. It could be difficult even for an experienced surgeon. It's the most erratic biliar duct malformation, and there are near 500 cases reported.(1)

Case presentation. We present a case report of a 44 years old female patient, with abdominal pain in right superior quadrant, history of jaundice and acholia, with higher hepatic enzymes and direct bilirubin, with high probability of Choledocholithiasis. The images had not finding of the gallbladder (ultrasonography, Magnetic Resonance). The endoscopic retrograde colangiopancreatography (ERCP) was done, without removal of lithiasis and it used stent.

Finally we did laparoscopy common bile duct exploration, and the surgery confirmation of agenesis of the gallbladder, with mechanic lithotripsy, and the success with total resolution of the pathology in the posterior medical control.

Conclusion. Agenesis of the gallbladder is a rare pathology that not many surgeons have the opportunity to treat. However, a surgeon must be prepared for any malformation and anatomical variant.

RESUMEN

Introducción. Una de las cirugías electivas que más desarrolla el cirujano general en adultos, es la colecistectomía. Sin embargo, el cirujano debe estar preparado para múltiples hallazgos, entre ellas las malformaciones.

El caso más exótico que puede encontrar el mismo, es la agenesis de la vesícula biliar, el cual puede desorientar completamente a un cirujano incluso experimentado, debido a que es la malformación con más baja incidencia de las vías biliares y sólo hay cerca de 500 casos reportados en la literatura.¹

Presentación del caso. Se presenta el caso de una paciente de 44 años, con cuadro clínico de dolor abdominal en cuadrante superior derecho, historia clínica de ictericia y acholia, con elevación del perfil hepático (hiperbilirrubinemia directa) y alta probabilidad de coledocolitiasis. En los estudios imagenológicos (Ultrasonografía y Resonancia Nuclear Magnética de Vías biliares), no hubo hallazgo de vesícula biliar.

Por ende, se realizó la colangiografía pancreática retrograda endoscópica (CPRE) en la cual no se logró la extracción de cálculos, y requirió uso de Endoprótesis. Finalmente, el tratamiento derivó a exploración de Vías biliares por laparoscopia, en donde se confirmó el hallazgo de agenesis de vía biliar sospechado por la Resonancia Magnética y ecografías previas, se realizó entonces litotripsia mecánica dirigida con resolución completa del cuadro clínico. Y seguimiento posterior exitoso, con mejoría de la sintomatología inicial de la paciente.

Conclusión. La agenesis vesicular una patología extraordinaria que incluso el cirujano general no se pueda encontrar alguna vez en su vida. Sin embargo, este debe estar preparado para todas las malformaciones y variantes anatómicas.

INTRODUCTION

Agenesis of the gallbladder is the least frequent malformation of the bile duct, with a

variable incidence between 0.01 and 0.06%, according to the literature, although it may be lower, with a ratio women to men of 3:1 (1). This condition was first described by Lemery in 1701, although other authors cite Bergman in 1702 as the first (2). The literature shows about 400 case series in total, which is why this case and literature review are relevant.

Agenesis of the gallbladder is not an isolated malformation, since studies show great association with other cardiovascular, genitourinary and central nervous system conditions in up to 15-33% of the cases, specifically pulmonary agenesis, tetralogy of Fallot, and anomalies in the limbs and in the genitourinary tract (1,3-6).

Most case series have been presented by Kumar, who classifies patients with agenesis of the gallbladder into three groups: a) asymptomatic patients (35%) diagnosed after performing studies to establish another cause; b) symptomatic patients (50%), of which 33% have a dilated primary bile duct and 33% lithiasis in the main bile duct, and c) children with more complex congenital anomalies (15%) such as lung agenesis, tetralogy of Fallot, and abnormalities of the limbs or the genitourinary system, which are often incompatible with life (7).

Moreover, if information relates only to symptomatic gastrointestinal cases, the statistics become more revealing, since 34% of them present with acid-peptic disease, and 50% are symptomatic with respect to pathology of the bile duct (7). Additionally, if only patients with biliary tract symptoms are considered, 33% present with dilation of the bile duct and 33% with choledocholithiasis, while the remaining cases report sphincter of Oddi dysfunction. With this in mind, it is possible to conclude that vesicular agenesis is a risk factor for such pathologies, as some authors have suggested (1,6-9).

CASE PRESENTATION

44-year-old woman from Bogotá D.C., mestizo, who was initially treated in the outpatient clinic for pain in the epigastrium and in the right hypochondrium, exacerbated by the intake of fatty foods, with approximately one year of evolution. The symptoms led to conclude a clinical picture suggestive of vesicular lithiasic pathology, so an ambulatory ultrasound was performed, showing no gallbladder, an intrahepatic and extrahepatic bile duct of normal caliber, and a 6 mm common bile duct. A subsequent esophagogastroduodenoscopy discarded acid-peptic disease, so a magnetic resonance cholangiography (MRC) was requested.

Two weeks after the initial consultation, the patient was admitted to the emergency department due to a clinical picture of three days of evolution consisting of abdominal pain in the epigastrium, which radiated to the back, and subjective fever. No emesis nor irritating urinary symptoms were observed, but choluria without acholia.

The patient presented the following surgical history: tubal ligation and right hip osteotomy. Upon physical examination, mild jaundice and pain were observed in the right hypochondrium and the epigastrium, without a positive Murphy sign nor signs of peritoneal irritation.

Paraclinical tests yielded the following results: leukocytes: 13 395, N% 87; Hb: 14; platelets: 344 000; amylase 34 U/L; total bilirubin: 4.66 mg/dL; direct bilirubin: 4.09 mg/dL; indirect bilirubin: 0.57 mg/dL; alkaline phosphatase: 1292 IU/L.

For its part, MRC showed generalized dilation of the intrahepatic and extrahepatic bile ducts, common bile duct with an average dilation of 1 cm, with presence of hyperintense faceted images in T2. Gallbladder was not identified (Figure 1).

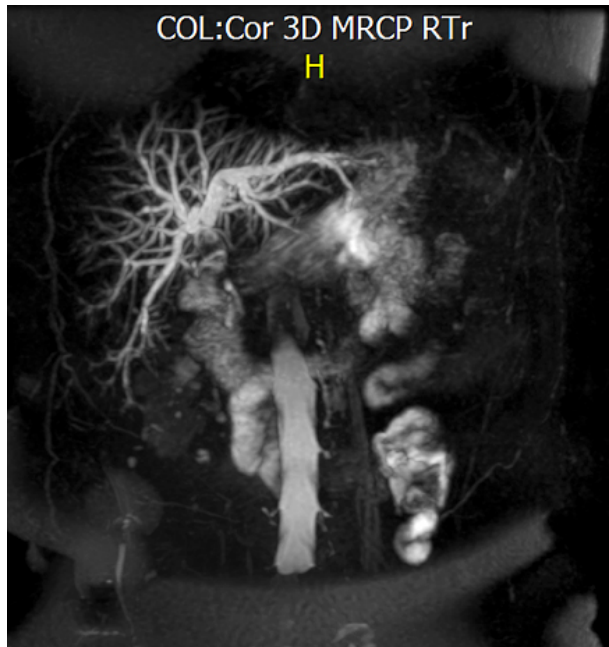


Figure 1. MRC - 3D reconstruction of the coronal section in the bile duct. Note the absence of gallbladder.

Source: Own elaboration based on the data obtained during the study.

Since several aspects indicated a high probability of choledocholithiasis, an endoscopic retrograde pancreatic cholangiopancreatography (ERCP) was performed, revealing a dilated, tortuous, and impacted intrahepatic bile duct, with no possibility of extraction, therefore, placing a stent was decided. Consequently, the case was taken to a surgical board to perform laparoscopic bile duct exploration.

During the procedure, the following findings were observed: absence of gallbladder, edematous biliary tract with duodenum adhesion, iatrogenic duodenum lesion of 5 mm (during the release of adhesions) and choledocholithiasis.

The procedure was performed by plas-tron adhesiolysis, primary duodenorrhaphy with absorbable suture by laparoscopy, and bile duct exploration by laparoscopy plus mechanical lithotripsy.

In the postoperative period, the patient presented a good evolution, with normalization

of the liver profile and successful discharge after five days. Ambulatory follow-up showed an asymptomatic patient, without episodes of choloria, acholia or pain, so it was concluded that pain was completely resolved. Likewise, the patient showed tolerance to food; however, the patient did not attend subsequent follow-up sessions.

DISCUSSION

Agnesis of the gallbladder is a rare pathology that not many surgeons have the opportunity to treat. However, a surgeon must be prepared for any malformation and anatomical variant; actually, Skandalakis (10) points out vesicular triplication, which includes, agnesis of the gallbladder and how to act when it is suspected.

It should be noted that before 1950, ultrasound studies were not available, so cholelithiasis was diagnosed when oral cholecystography showed that the gallbladder was excluded (it was not observed in radiological images). When the patient underwent cholecystectomy, surgeons were surprised to notice the absence of the gallbladder.

Fortunately, today surgeons can plan procedures in an optimal manner, since ultrasound has a performance close to 80 or 90%, and is sufficient in most cases. However, in a case such as the one presented here, in which a scleroatrophic vesicle, chronic cholecystitis and acalculous cholecystitis were identified — the latter using tomographic studies—, agnesis of the gallbladder cannot be disregarded. In these cases, other specialized methods such as MRC (Figure 2), endoscopic ultrasonography, ERCP, among others, can be helpful. (9).

Before ultrasounds, Frey performed the largest amount of surgeries involving vesicular agnesis, establishing a triad for its diagnosis

under the following criteria: absence of inflammatory signs or fibrosis in the vesicular bed, complete dissection looking for an ectopic

gallbladder (this dissection was extensive, including dissection of the left hypochondrium), and intraoperative cholangiography (6).

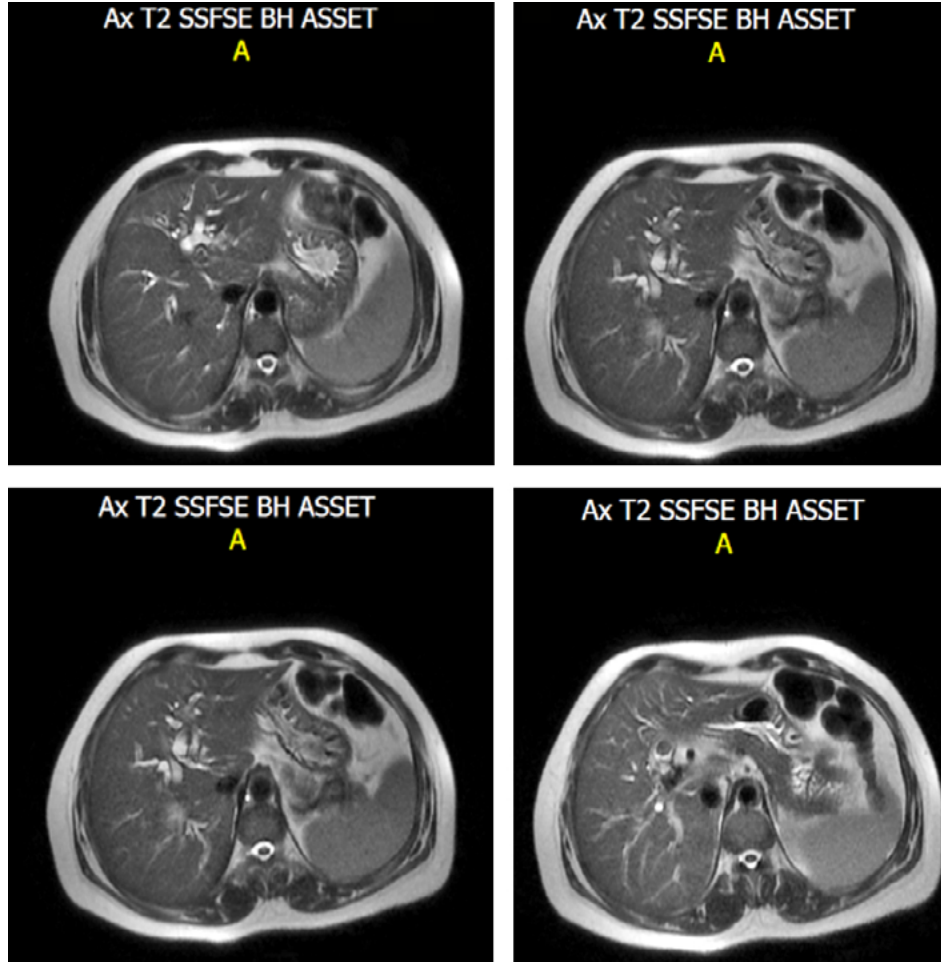


Figure 2. MRC sequence in T2 of the bile duct. Note the absence of gallbladder.

Source: Own elaboration based on the data obtained in the study.

However, this procedure was done before the laparoscopic era and the arrival of MRC. Therefore, today it is considered that, during the surgical act, fibrous remnant or scar should be sought; the vesicular ectopic position should be discarded (intrahepatic, adhered to the left lobe, falciform ligament, retroperitoneal or in the anterior abdominal wall), and, according to the ability or criterion of the surgeon, intraoperative cholangiogra-

phy should be performed, although it is not mandatory, as stated by Frey (11).

However, despite the fact that postoperative ERCP/MRC should inevitably be performed, in this case, MRC should always be considered, since agenesis is an exotic pathology and the infrequent vesicular positions mentioned above can be overlooked (3 -5,7-14), thus avoiding, in the first instance, the risks of ERCP when there is no lithiasis in the

primary bile duct (choledocholithiasis) (Figure 3). However, in the presence of agenesis, ERCP has been reported as not effective due,

in part, to dysfunction of the sphincter of Oddi, so many patients need surgery and lithotripsy, as happened in this case (15).

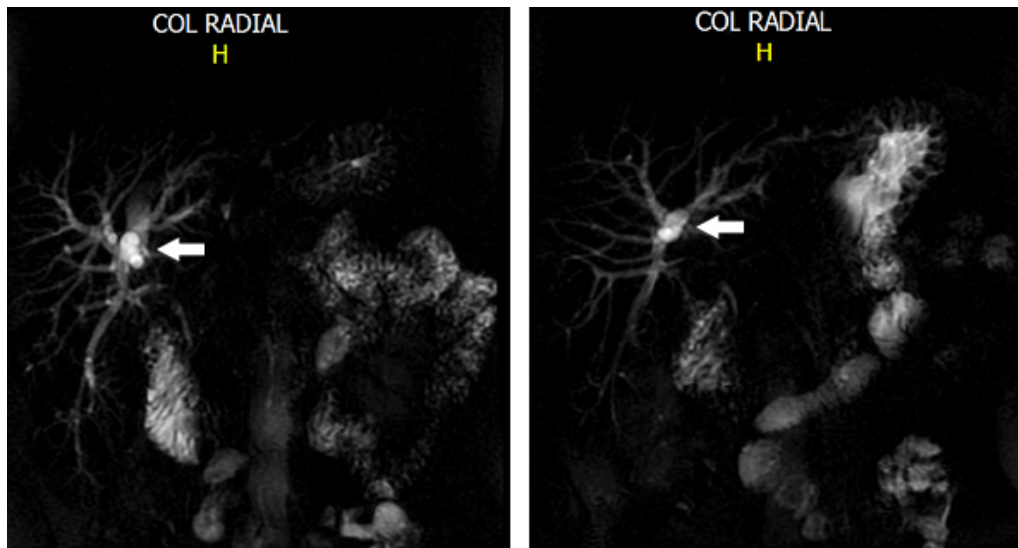


Figure 3. 3D reconstruction of the bile duct. Note the multiple hyperintense images, the major ones (yellow arrow) correspond to lithiasis of the bile duct.

Source: Own elaboration based on the data obtained in the study.

Finally, the safety vision of Strasberg (16) is recommended, since it is the most effective way to prevent bile duct injury as exposed in said reference.

Unfortunately, long-term follow-up was not possible, since the patient, as mentioned before, did not attend the subsequent controls, which is common in the Colombian context.

CONCLUSIONS

Although it is not possible to make generalizations based on the current evidence, other authors report two more cases in the region (17); therefore, the following steps are advisable when the intraoperative gallbladder cannot be identified:

- Looking for the ectopic gallbladder
- Looking for a scar in the liver bed that suggests agenesis

- Not manipulating excessively the bile duct
- Performing intraoperative cholangiography depending on the medical center, preference and experience of the surgeon
- Unfailingly performing a postoperative MRC

CONFLICT OF INTERESTS

None stated by the author.

FUNDING

None stated by the author.

INFORMED CONSENT:

The patient signed an informed consent during hospitalization for the completion of this report.

REFERENCES

1. **Fernández GL, Blanco FG, Párraga del Moral J, Grau-Talens L, Vinagre-Velasco LM, Téllez de Peralta FJ.** Agenesis of the gallbladder confirmed by nuclear magnetic resonance cholangiogram. *Rev Esp Enferm Dig.* 2002; 94(5):286-7.
2. **Cavazos -García R, Díaz-Elizondo JA, Flores-Villalba E, Rodríguez-García HA.** Gallbladder agenesis. Case report. Agenesis de la vesícula biliar. Reporte de caso. *Cir Cir.* 2015;83:424-8. doi: <http://doi.org/cf2v>.
3. **Waisberg J, Pinto PE Jr., Gusson PR, Fasano PR, de Godoy CD.** Agenesis of the gallbladder and cystic duct. *Sao Paulo Med J.* 2002;120(6):192-4.
4. **Bani-Hani KE.** Agenesis of the gallbladder: difficulties in management. *J Gastroenterol Hepatol.* 2005;20(5):671-5.
5. **Flores-Valencia JG, Vital-Miranda SN, Mondragón-Romano SP, Garza-Salinas LH.** Agenesis vesicular: reporte de caso. *Rev Med Inst Mex Seguro Soc.* 2012;50(1):63-6.
6. **Richards RJ, Taubin H, Wasson D.** Agenesis of the gallbladder in symptomatic adults. A case and review of the literature. *J Clin Gastroenterol.* 1993;16(3):231-3.
7. **Vijay KT, Kocher HH, Koti RS, Bapat RD.** Agenesis of gall bladder. A diagnostic dilemma. *J Postgrad Med.* 1996;42(3):80-2.
8. **Orúe-Elorza JE.** Agenesis de la vesícula biliar. Presentación de un caso estudiado por RM-colangiografía. *Cirugía Española.* 2016;9(4):427-9.
9. **Muñoz HJ, Quirarte CC, Arribas MA, Gónzaga SM, Cruz RO, Muñoz GR.** Agenesis de vesícula biliar. Reporte de un caso y revisión de la literatura. *Rev Mex Cir Endoscop.* 2011;12(1):35-7.
10. **Skandalis JE, Branum GD, Colborn GL, Wediman TA, Sakandalakis PN, Skandalis LJ et al.** Vías biliares extrahepáticas y vesícula biliar. En: Skandalakis J.E. Skandalakis Cirugía. Madrid: Marban; 2013. p. 974-1024
11. **Meilstrup JW, Hopper KD, Thieme GA.** Imaging of gallbladder variants. *AJR.* 1991;157:1205-8. doi: <http://doi.org/cf25>.
12. **Pérez-Moreiras MI, Couselo-Villanueva JM, Maseda-Díaz DO, Arija-Val VF.** Una verdadera agenesia vesicular. *Cir Esp.* 2007;82(4):246-7.
13. **Affí ES, Atef H, Wael B.** Agenesis of the gallbladder with primary choledochal stones. *Med Princ Pract.* 2006;15:379-81. doi: <http://doi.org/bwn9zg>.
14. **Yener O, Buldanlı MZ, Eksioğlu H, Leblebici M, Alimoğlu O.** Agenesis of the gallbladder diagnosed by magnetic resonance cholangiography: report of a case and review of the literature. *Prague Med. Rep.* 2015;116(1):52-6. doi: <http://doi.org/f7fx5f>.
15. **Tjaden J, Patel K, Aadam A.** Gallbladder Agenesis with Refractory Choledocholithiasis. *Case Reports in Gastrointestinal Medicine.* 2015; Article ID 747931. <http://doi.org/gb5r6m>.
16. **Strasberg SM.** A teaching program for the "culture of safety in cholecystectomy" and avoidance of bile duct injury. *J Am Coll Surg.* 2013; 217(4):751. doi: <http://doi.org/cf26>.
17. **Prieto RG, Andrade E, Martínez H, Silva E, Brando C, Torres A.** Agenesis de la vesícula biliar. *Rev Colomb Cir.* 2015;30:193-7.