



<https://doi.org/10.15446/cr.v5n2.77093>

MULTIPLE ORGAN FAILURE CAUSED BY POISONOUS CONTACT WITH A *LONOMIA SP* CATERPILLAR. CASE REPORT

Keywords: Lonomia; Larva; Lepidoptera.
Palabras clave: Lonomia; Larva; Lepidópteros.

Wilson Hernando Pineda-Amaya

Universidad de Ciencias Aplicadas y Ambientales
- Faculty of Health Sciences - Medical Program -
Bogotá D.C. - Colombia.

Hospital del Sarare Empresa Social del Estado -
Intermediate Care Unit - Saravena,
Arauca - Colombia.

Nohemí Pastrana-Ricaurte

Hospital del Sarare Empresa Social del Estado -
Intermediate Care Unit - Saravena,
Arauca - Colombia.

Universidad de Pamplona - Faculty of Health Sciences -
Nursing Program - Pamplona,
Norte de Santander - Colombia.

Corresponding author

Wilson Hernando Pineda-Amaya.
Faculty of Health Sciences, Universidad de Ciencias
Aplicadas y Ambientales.
Bogotá D.C. Colombia.
Email: wilsonpineda1107@hotmail.com

RESUMEN

Introducción. El accidente lonómico se ha convertido en un evento de gran interés, ya que supone una problemática de salud pública enfocada en las comunidades rurales y un reto para el personal de salud dadas las múltiples complicaciones, el difícil diagnóstico y las variantes terapéuticas.

Presentación del caso. Paciente masculino de 41 años quien tuvo contacto con oruga del género *Lonomia* sp. y presentó síntomas de sangrado y posterior falla multiorgánica que se resolvió con el uso de suero antilonómico.

Discusión. Se presenta un cuadro clínico que progresó a falla multiorgánica y síndrome hemorrágico asociado a dificultades en su diagnóstico y que requirió intervención terapéutica en primer nivel de urgencia con posterior necesidad de tratamiento en un centro de mayor complejidad por deterioro y no disponibilidad de suero antilonómico.

Conclusiones. A partir de las estrategias de intervención médica intrahospitalaria, la administración del suero lonómico y el seguimiento del paciente a través del sistema, se pudo constatar la mejoría en el estado de salud y dar el alta médica. Es importante poner en tensión los conocimientos de los profesionales en salud que atienden estos casos en las zonas rurales y la disponibilidad del suero de tratamiento.

ABSTRACT

Introduction: Lonomic accidents have become of great interest as they represent a public health problem in rural communities. These accidents are challenging for health personnel given their multiple associated complications, difficult diagnosis and therapeutic variants.

Case presentation: This is the case of a 41-year-old male patient who had contact with a caterpillar of the genus *Lonomia* sp. He presented with symptoms of bleeding and subsequent multiple organ failure that resolved with the use of antilonomic serum.

Discussion: The patient presented with symptoms that progressed to multiple organ failure and associated hemorrhagic syndrome due to the difficulties for diagnosis. He required therapeutic intervention in a primary care institution with subsequent need for treatment in a more complex center considering the deterioration and non-availability of the antilonomic serum.

Conclusions: Based on in-hospital medical intervention strategies, the administration of the lonomic serum and the patient's follow-up through the system, it was possible to confirm the improvement of his health condition and discharge him. It is important to stress the knowledge of the health professionals who treat these cases in rural areas and the availability of the serum.

INTRODUCTION

Lonomic accident or lepidopterism- erucism is understood as the disease caused by direct contact with caterpillars of the family *Lonomia* sp. Currently, there are about 26 variants of this species distributed throughout the Americas, where different denominations have been used to describe these larvae: fire caterpillars, churruscus (Colombia) or muchiras (southern Colombia and Ecuador). (1)

Accidents and diseases caused by poisonous terrestrial animals, such as caterpillars, amphibians and myriapods, or aquatic animals, are rarely reported in Colombia, and there is little information on their diagnosis and management. Culturally speaking, it is known that most affected people belong to indigenous communities and are exposed due to their economic and social activities, sociocultural

particularities, the scarce or lack of protection of the hands, feet and skin, and even by the use of *Phyllobates* sp. venom in hunting activities. (2)

The caterpillars of the *Saturniidae* species (Figure 1) are characterized by pointed and branched spicules, bristles or hairs that contain a complex mixture of enzymes and toxins. (3) These substances are released into the skin after contact, causing activation of the kinin–kallikrein system and fibrinogen-lytic enzymes that produce a wide arrange of signs and symptoms because of the alteration in the coagulation cascade involving factors VIII-XIII-X. (3,4) Authors have reported cases of caterpillar poisoning that start with multiple symptoms at the inoculation site and then progress to general symptoms. Initial symptoms include general malaise, headache and nausea, followed by hemorrhagic syndrome, which leads to multiple organ failure and even death. (5)



Figure 1. *Lonomia obliqua* larva.

Source: Taken from Manosso (6).

Blood dyscrasia is closely correlated to the symptoms and is the most serious complication; it is usually established within the first 48 hours after contact. Moreover, hemorrhagic lesions

may vary from ecchymotic lesions to episodes of massive and intraparenchymal bleeding. (7)

The main treatment involves the use and administration of antilonomic serum, depending

on the classification and description of symptoms in the patient (Table 1). The process that counteracts the mechanisms of the pathological lesion and reduces the symptomatology is currently known. (7-9)

Table 1. Clinical classification of Ionomia accident.

| Classification | Description |
|----------------|---|
| Mild | Patient exposed to caterpillars who has only local but no hemorrhagic symptoms. |
| Moderate | Patient with local symptoms, hemorrhagic signs and symptoms, and involvement of mucous membranes and skin, without vasopressor support. |
| Severe | Patient with hemodynamic instability, hemorrhagic syndrome that involves multiple organs and multiple organ failure. |

Source: Elaboration based on Arocha-Piñango (4).

CASE PRESENTATION

A 41-year-old male patient from the Curipao indigenous ethnic group, residing in the municipality of Tame, Arauca (Colombia), with a history of chronic gastritis without pharmacological treatment and no other relevant condition, was admitted at a secondary healthcare center on September 26, 2016, with an apparent snakebite injury diagnosed in a primary healthcare center. The man reported that around 10:00 a.m. the day before, he left his home to carry out agricultural work and had contact with an animal (unidentified at first) in the back side of the right hand (Figure 2). He also reported the insertion of approximately 20 bristles into the skin that caused him intense localized pain, similar to stinging pain, with an intensity of 8/10 on a pain scale, which were removed a few minutes later with a sharp object (knife). After that, he expressed feeling irradiation of pain towards

the elbow, sensation of paresthesia, pruritus, edema, redness and heat on the lesion site. He said that he applied a topical fungal cream 20 minutes after contact, improving the symptoms, pain and redness; however, edema of the hand persisted (Figure 2).

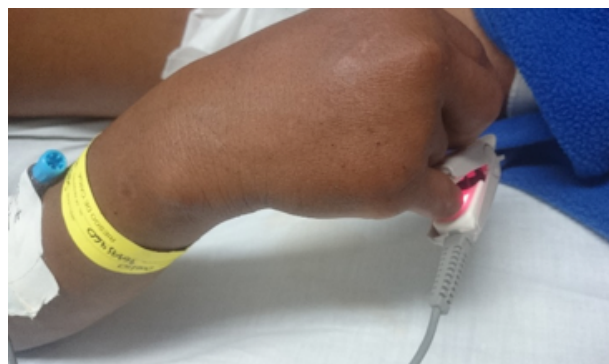

Figure 2. Primary site of contact with caterpillar *Lonomia* sp.
Source: Document obtained during the study.

The man manifested the onset of global headache and hematemesis —approximately 30 episodes during the day— and burning pain in the epigastric region without irradiation, and generalized arthralgia. The following day, he decided to seek medical help at the nearest center (primary healthcare center), where he reported persistence of symptoms and appearance of bleeding gums. The medical assessment resulted in a diagnostic impression of snakebite accident, and management with omeprazole and intravenous fluid therapy was initiated. Laboratory reports indicated 13 000 leukocytes, 86% neutrophilia, 14% lymphocytes, and prothrombin time and partial thromboplastin time > 1 minute; no platelet count was available.

He was referred to a secondary healthcare center, where he was admitted for evaluation and management by an internist. The vital signs on admission were: heart rate: 87 /min, respiratory rate: 19/min, blood pressure: 146/83 mmhg, oxygen saturation: 98%, and fraction of inspired oxygen: 0.21. On initial physical examination,

slight skin paleness was observed, along with active bleeding in the gums, especially in the dental fracture of the right first molar (Figure 3); cardiopulmonary aspects without alterations; soft abdomen with pain in epigastrium region; and right upper limb with edema located in the dorsum, erythematous punctiform lesions, without redness or heat, and mild pain on palpation. No strength deficiencies were observed during

the neurological examination and sensitivity was preserved.

Finally, two episodes of hematemesis occurred during hospitalization, for which hematology tests and blood chemistry were requested. Table 2 presents the results of the laboratory tests carried out on admission, revealing an increase in kidney function and alteration of liver function; deterioration of leukocyte and platelet function is also evident.

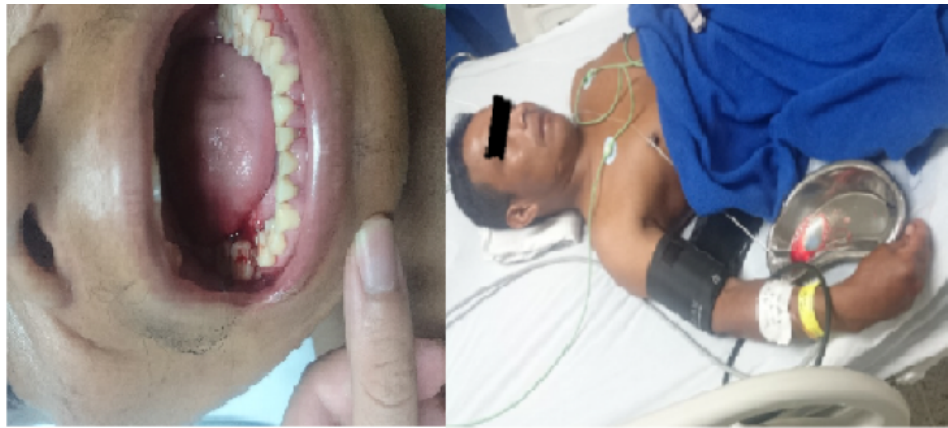

Figure 3. Bleeding of the gums.

Source: Document obtained during the study.

Table 2. Lab test reports obtained during clinical evolution.

| Tests | 25/09/16 | 26/09/16 | 27/09/16 | 27/09/16 | 28/09/16 | 29/09/16 | 30/09/16 | 01/10/16 | 02/10/16 |
|--|---|--|---|---|--|----------|---|--|----------|
| Hematocrit for men: 42-54% | | hematocrit: 40.5% | hematocrit: 24.8% | hematocrit: 18.6% | hematocrit: 20.1% | | hematocrit: 16.9% | hemoglobin: 27.4% | |
| White blood cell count: 5 000-10 000/mm ³ | leukocytes: 13 000, neutrophils: 83%, lymphocytes: 8% | leukocytes: 9 400, neutrophils: 83%, lymphocytes: 8% | leukocytes: 18 200, neutrophils: 97%, lymphocytes: 2% | leukocytes: 11 192, neutrophils: 94%, lymphocytes: 2% | leukocytes: 11 160, neutrophils: 87% lymphocytes: 6% | | leukocytes: 9 100, neutrophils: 76.1%, lymphocytes: 17.1% | leukocytes: 9 360 neutrophils: 71.3%, lymphocytes: 14.9% | |
| Manual platelet count: 150 000-450 000 | | platelets: 212 000 / mm ³ | platelets: 178 500 / mm ³ | platelets: 86 100 / mm ³ | platelets: 52 000 / mm ³ | | platelets: 135 000 / mm ³ | platelets: 192 000 / mm ³ | |

Continues.

| Tests | 25/09/16 | 26/09/16 | 27/09/16 | 27/09/16 | 28/09/16 | 29/09/16 | 30/09/16 | 01/10/16 | 02/10/16 |
|--|-----------------------------|---|-------------------------------|---------------------------------------|---|-------------------------------------|--|--|--|
| Coagulation times PT: 12-15 seconds PTT: 25-35 seconds | PTT >1 minute, PT >1 minute | PTT >2 minutes, PT >2 minutes | PTT >2 minutes, PT >2 minutes | PTT: 106.1 seconds, PT: >2 seconds | PTT: 35.9 seconds, PT: 26.2 seconds | PTT: 23.6 seconds, PT: 17.9 seconds | | PTT: 21.2 seconds, PT: 14.3 seconds | |
| Transaminases GOT: 10-40 u/L GPT: 7-40 u/L | | GOT: 217 u/L, GPT: 42 u/L | GOT: 217 u/L, GPT: 42 u/L | | | | GOT: 30 u/L, GPT: 25 u/L | | |
| Kidney function men Creatinine: 0.6 and 1.2 mg/dL BUN: 10 and 20 mg/dL | | 3.2 mg/dL | | Creatinine: 3.27 mg/dL, BUN: 43 mg/dL | Creatinine: 2.65 mg/dL, BUN: 44.5 mg/dL | Creatinine: 2.48 mg/dL | Creatinine: 1.24 mg/dL, BUN: 27.7 mg/dL | Creatinine: 1.09 mg/dL, BUN: 17.6 mg/dL | Creatinine 1.03 mg/dL BUN: 15.2 mg/dL |
| Glucose: 60-110 mg/dL | | 95 mg/dL | | | | | | | |
| Electrolytes Potassium 3.5-4.5 mEq/L Sodium: 135-145 mEq/L | | Potassium: 4.0 mEq/L, Sodium: 143 mEq/L | | | | Potassium: 2.9 mEq/L | Potassium: 3.41 mEq/L, Sodium: 146.7 mEq/L | Potassium: 3.05 mEq/L, Sodium: 145 mEq/L | Potassium: 3.1 mEq/L, Sodium: 139 mEq/L |

PTT: thromboplastin time; PT: prothrombin time; GOT: glutamic-oxalacetic transaminase; GPT: glutamic-pyruvic transaminase; BUN: blood urea nitrogen.

Source: Own elaboration.

In order to assess and control hemodynamics, the patient was taken to intermediate care and received treatment with fluid therapy of 0.9% saline solution, 300mg hydrocortisone single dose, 6 vials of antiophidic serum IV, antibiotic management with third generation cephalosporins (ceftriaxone) 1g every 12 hours, 600mg lincosamides (clindamycin) every 6 hours, 1 vial of tranexamic acid every 8 hours, 1 mg vitamin k every day, 40mg omeprazole every 12 hours,

20mg simple hyoscine and 10mg metoclopramide every 8 hours. Control lab tests were subsequently requested based on his clinical evolution and according to the need.

Medications were not applied intramuscularly due to the risk of hematomas as an adverse event. After initiating pharmacological administration and upon observation, it was concluded that there were no hemodynamic alterations, no need for vasopressor support,

no cardiac frequency alterations, oxygen saturation of 98%, and fraction of inspired oxygen of 0.21. Regarding the neurological condition, there were no focalizations or new episodes of hematemesis, no increase in hand edema, but there was persistence of pain in the epigastrium region and bleeding in the gums. Management with transfusion of five units of frozen plasma (Table 2) was initiated and a chest X-ray was performed to establish pulmonary involvement, which did not show relevant acute lesions.

Subsequently, a new physical examination was performed, leading to the impression of lonomic accident based on the recognition of the animal by the patient from graphic material, thus confirming suspicion of diagnosis of poisoning by *Lonomia* sp. Therefore, the Departmental Health Secretariat and the Bogotá Health Secretariat were immediately notified; they confirmed the availability of five vials of antilonomic serum in a tertiary referral hospital to where he was transferred for comprehensive management. He was admitted to this hospital with a diagnostic impression of septic shock versus hypovolemic, lonomic accident, upper digestive tract bleeding and normochromic microcytic anemia.

The patient was immediately assessed by the internal medicine service, which indicated the need for intravenous application of antilonomic serum and subsequent control tests for follow-up. During the application of the five vials of serum, no adverse events or reactions were observed; additionally, hemodynamic control did not present deterioration, neurological state was preserved and bleeding in the gums persisted.

With the passage of time, the bleeding in the gums resolved and control lab tests showed improvement and slight prolongation of coagulation times; there was also a decrease in neutrophilia without hemodynamic decompensation, but thrombocytopenia and a decrease in serum

creatinine persisted. During hospitalization, a complete ultrasound of the abdomen was performed, showing liver with some degree of parenchymal destructuring of micro nodular aspect and findings compatible with diffuse liver parenchyma lesion, possible alcoholic hepatic cirrhosis, and bilateral pleural effusion. Modification of parenteral fluids was indicated considering possible signs of overload, as well as transfusion of two units of red blood cells.

During the night, a new transfusion of red blood cells was made. However, the patient showed no signs of hemodynamic instability and his neurological state was preserved. Correction of acute anemia, preserved kidney function, correction of hypokalemia, preserved coagulation times and corrected thrombocytopenia were observed; there was no evidence of bleeding in the gums. He was finally discharged to continue medical treatment and care on an outpatient basis.

DISCUSSION

Cases associated with poisonous contact with caterpillars that do not cause hemorrhagic syndrome have been described, therefore, not all poisoning mechanisms are the same and different enzymatic mechanisms may be involved. (10) Some species only cause acute kidney failure as the main complication, but this could also be caused by ischemia (Table 1). (11)

Despite the lack of case reports, this type of cases has been reported in Brazil, Venezuela, Argentina and French Guiana in Latin America. According to statistics, between 1989 and 2005, 354 cases were reported in Brazil, with a lethality that dropped from 20% in 1995 to 15% in 1998, being intracranial bleeding the cause of death in 50% of cases. (12)

In Colombia, the incidence of lonomic accidents and knowledge of this pathology is low,

making epidemiological notification difficult. According to the Colombian Toxicological Research, Management and Information Center, between 2006 and 2010, 68 cases of lepidopteran accidents occurred due to spontaneous and passive reporting, being the sixth cause of incidence of accidents by poisonous animals, with a relative

frequency of 4% (Figure 4). (13) In 2000, the first cases of hemorrhagic syndrome secondary to *Lonomia* sp were reported; they occurred in the departments of Guainía, Valle del Cauca, Boyacá, Caldas, Antioquia, Cundinamarca and Meta, each case with especial characteristics concerning their evolution (Figure 5). (14)

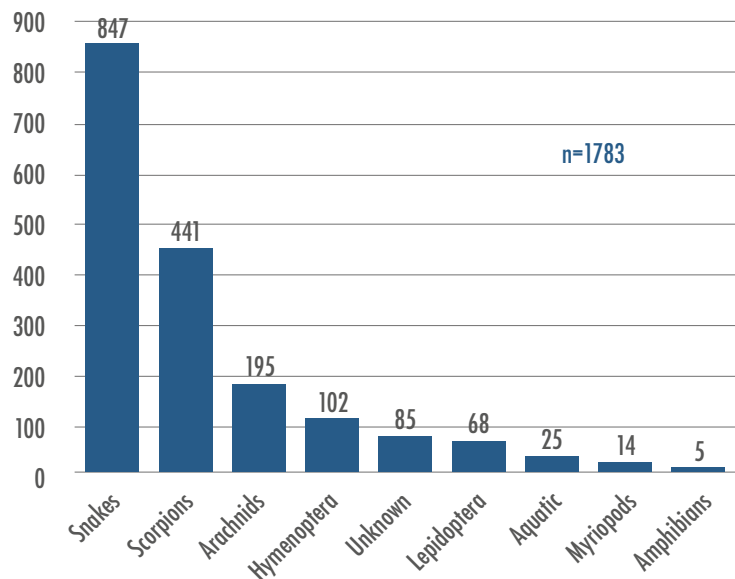


Figure 4. Frequency of accidents caused by poisonous animals in Colombia, 2006-2010.

Source: Elaboration based on Rodríguez-Vargas *et al.* (13).

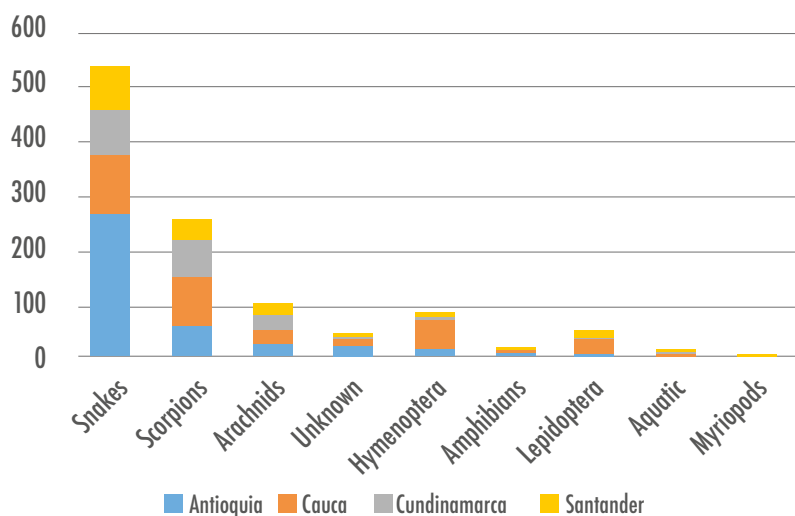


Figure 5. Frequency of accidental poisoning by department in Colombia. 2006-2010.

Source: Elaboration based on Rodríguez-Vargas *et al.* (13).

It should be noted that there is currently evidence of under-reporting, since it is impossible to notify a lonomic accident that was previously reported as ophidic, as in this case. In addition, this could be correlated with the lack of knowledge of health personnel to identify cases of lonomism. This last aspect was evident in the present case as it was initially treated as an ophidic accident and there were delays in the care process; consequently, the management of the patient was only adequate until he was referred to a high complexity health center.

In addition, it should be noted that the highly specialized professionals who attended the present case had basic notions and some degree of expertise in this accident and subsequent pathological manifestation. Basic knowledge for proper management is vital in correlations involving poor performance or intervention and the development of a pathology associated with injury to multiple vital organs, and even death.

CONCLUSIONS

The use of antilonomic serum therapy led to complete recovery 17 hours after initiating the treatment, without the presence of associated complications and coincides with the management described in other reports. (14) However, it is important to emphasize that management with intrahospital therapy allowed for a positive evolution of the patient and early diagnosis.

One of the disagreements between the system and health care lies in the lack of knowledge of the pathology and the lack of availability of fresh frozen plasma, devices for transfusion of red blood cells and antilonomic serum. For this reason, it was necessary to refer the patient to hospitals of all tiers of care, affecting his clinical picture and putting at risk his vital organs. It is important to mention that

the latter two reasons are the most common causes of worsening. (14)

It is necessary to identify the medical centers and professionals that are in the areas where this species lives in order to provide training according to the socio-demographic context and to provide resources that allow them to have the necessary inputs to improve medical interventions and obtain better health outcomes.

CONFLICT OF INTEREST

None stated by the authors.

FUNDING

None stated by the authors.

ACKNOWLEDGEMENTS

To all the institutions and health personnel who helped us to obtain the patient's medical history. To the Curipao indigenous community, to the translators, and to the patient himself for consenting the publication of his case.

REFERENCES

1. **Pinto AF, Berger M, Reck J Jr, Terra RM, Guimarães JA.** Lonomia obliqua venom: In vivo effects and molecular aspects associated with the hemorrhagic syndrome. *Toxicon*. 2010;56(7):1103-12. <http://doi.org/cds7qh>.
2. **Rodríguez-Vargas AL.** Comportamiento general de los accidentes provocados por animales venenosos en Colombia entre 2006 y 2010, atendidos en el Centro de Investigación, Gestión e Información Toxicológica de la Universidad Nacional de Colombia [tesis de maestría]. Bogotá D.C.: Facultad de Medicina, Universidad Nacional de Colombia; 2012.

3. **Gómez JP.** lepidopterismo y erucismo en Colombia. *Revista Biosalud.* 2014;13(2):59-83.
4. **Arocha-Piñango CL.** Venenos de invertebrados y coagulación. In: *López-Borrasca A.* Hematología geográfica. Enciclopedia Iberoamericana de Hematología. Volumen IV. Salamanca: Ediciones Universidad de Salamanca.
5. **de Roodt AR, Salomón D, Orduña TA.** Accidentes por lepidópteros con especial referencia a *Lonomia* sp. *MEDICINA (Buenos Aires).* 2000;60(6):967-70.
6. **Manosso R.** The Powerpuff Girls [image]. Flickr; 2017.
7. **Berger M, Santi L, Beys-da-Silva WO, Oliveira FM, Caliarí MV, Yates JR 3rd, et al.** Mechanisms of Acute Kidney Injury Induced by Experimental *Lonomia obliqua* Envenomation. *Arch Toxicol.* 2015;89(3): 459-83. <http://doi.org/f63bs2>.
8. **Sánchez MN, Mignone-Chagas MA, Casertano SA, Cavagnaro LE, Peichoto ME.** Accidentes causados por la oruga *Lonomia obliqua* (Walker, 1855): Un problema emergente. *Medicina (Buenos Aires).* 2015;75(5):328-33.
9. **Lorini ML, Corseuil EE.** Aspectos Morfológicos de *Lonomia obliqua* Walker (Lepidoptera: Saturniidae). *Neotrop. Entomol.* 2001;30(3):373-9. <http://doi.org/d9vk6z>.
10. **Pineda D, Amarillo A, Becerra J, Montenegro G.** Síndrome hemorrágico por contacto con orugas del género *Lonomia* (saturniidae) en Casanare, Colombia: informe de dos casos. *Biomédica.* 2001;21(4):328-32. <http://doi.org/c7dq>.
11. **Ávila AA, Moreno A, Garzón A, Gómez AA.** Accidente Ionómico. *Acta Méd Colomb.* 2013;38(2):95-100.
12. **Peña-Vásquez W, Vásquez-Paz H, Vásquez-Becerra R, Chiappe-González A, Navincopa-Flores M, Ticona-Chávez E.** Niña con erucismo hemorrágico por *Lonomia* spp. reporte de un caso. *Rev Perú Med Exp Salud pública.* 2016;33(4):819-23. <http://doi.org/c7dr>.
13. **Rodríguez-Vargas AL, Rodríguez-Buitrago JR, Díaz-González GJ.** Comportamiento general de los accidentes provocados por animales venenosos en Colombia, 2006-2010. *Rev. salud pública.* 2012;14(6):1001-9.
14. **Ángel-Mejía R, Campuzano-Maya G, Vane-gas-Arroyave N.** Síndrome hemorrágico causado por orugas de mariposas. *Medicina & Laboratorio.* 2007;13(1-2):67-74.