



<https://doi.org/10.15446/cr.v5n2.78952>

SPONTANEOUS VULVAR HEMATOMA AS A RARE MANIFESTATION OF CONGENITAL HYPOFIBRINOGENEMIA. CASE REPORT

Keywords: Afibrinogenemia; Fibrinogen; Hematoma; Vulva.
Palabras clave: Afibrinogenemia; Fibrinógeno; Hematoma; Vulva.

Sebastián Felipe Sierra-Umaña

Universidad Nacional de Colombia
- Bogotá Campus - Faculty of Medicine -
Department of Internal Medicine
- Bogotá D.C. - Colombia.

Rafael García-Sánchez

Universidad de La Sabana
- Faculty of Medicine -
Department of Internal Medicine
- Chía, Cundinamarca - Colombia.

Laura Camila Urrutia-Corredor

Universidad El Bosque
- Faculty of Medicine - Medicine Program -
Bogotá D.C. - Colombia.

Jessica Tatiana Olarte-Luis

Dolli Yineth Cáceres-Galíndez
Universidad Nacional de Colombia
- Bogotá Campus - School of Medicine -
Medicine Program
- Bogotá D.C. - Colombia.

Corresponding author

Sebastián Felipe Sierra-Umaña.
Department of Internal Medicine,
Faculty of Medicine, Universidad Nacional de Colombia.
Bogotá D.C. Colombia. Email: sfsierrau@unal.edu.co

RESUMEN

Introducción. Los trastornos congénitos del fibrinógeno son una rara condición donde se presentan alteraciones cuantitativas y cualitativas del factor I, siendo asintomáticos la gran mayoría de pacientes.

Presentación del caso. Paciente femenino de 19 años con antecedente de hipofibrinogenemia congénita, quien cursa con hematoma espontáneo en vulva y presenta hipotensión, taquicardia, estupor y hematoma de 20cm en labio mayor derecho. Al ingreso, la joven registra hemoglobina 6.6 g/dL, fibrinógeno 74 mg/dL y prolongación de tiempos de coagulación. Se transfunden glóbulos rojos y crioprecipitados; luego se hace drenaje quirúrgico y reposición de fibrinógeno ajustando dosis acorde a fibrinógeno plasmático. La paciente presenta mejoría progresiva sin recurrencia hemorrágica y niveles de fibrinógeno en metas hasta egreso hospitalario.

Discusión. La afibrinogenemia y la hipofibrinogenemia hacen parte de los trastornos cuantitativos del factor I, con ausencia total para la primera y niveles < 150 mg/dL para la segunda. El hematoma espontáneo de vulva como manifestación hemorrágica severa no es una presentación habitual en pacientes sintomáticos; su tratamiento se basa en la reposición de fibrinógeno de forma individualizada y manejo quirúrgico cuando sea requerido.

Conclusión. La hipofibrinogenemia es una enfermedad rara, donde el reemplazo de fibrinógeno es uno de los pilares de tratamiento.

ABSTRACT

Introduction: Congenital fibrinogen disorders are rare conditions in which there are quantitative and qualitative alterations of factor I; the vast majority of patients are asymptomatic.

Case presentation: A 19-year-old female patient with a history of congenital hypofibrinogenemia presented with spontaneous vulvar hematoma along with hypotension, tachycardia, stupor and hematoma of 20cm in the right labium majus. On admission, the young woman had hemoglobin 6.6 g/dL, fibrinogen 74 mg/dL and prolonged clotting times. She received red blood cells transfusion and cryoprecipitates, followed by surgical drainage and intravenous fibrinogen replacement, adjusting the dose according to fibrinogen levels in plasma. The patient presented progressive improvement without hemorrhagic recurrence and fibrinogen levels within the target values until hospital discharge.

Discussion: Afibrinogenemia and hypofibrinogenemia are part of the quantitative factor I disorders; in the first case, there is total absence of circulating fibrinogen, and in the second case the levels are below 150 mg/dL. Spontaneous vulvar hematoma as a severe hemorrhagic manifestation is not frequent in symptomatic patients; its treatment is based on fibrinogen replacement in an individualized manner and surgical management when required.

Conclusion: Hypofibrinogenemia is a rare disease, and fibrinogen replacement is one of the mainstays of treatment.

INTRODUCTION

Hypofibrinogenemia is a congenital disorder consisting of low levels of fibrinogen, a key glycoprotein for the hemostasis system and inflammatory response. (1,2) This abnormality occurs as a result of a heterozygous mutation in one of the three genes encoding for the fibrinogen protein chains and autosomal recessive inheritance. There is no exact data on its incidence, since most patients are asymptomatic or do not have clinically significant bleeding. When severe hemorrhagic manifestations, such as gastrointestinal bleeding with unknown etiology, are observed, the corresponding studies should be carried out to look for the cause. (1,3-6)

The severe form of hypofibrinogenemia is similar to afibrinogenemia (1), and also manifests itself mainly in the neonatal period, in 85% of cases through umbilical cord bleeding. Its presentation in older individuals is rare, and its hemorrhagic manifestations may be gastrointestinal, genitourinary, cutaneous, by spontaneous splenic rupture and central nervous system; the latter is the main cause of death in these patients. (2,3,5)

To diagnose hypofibrinogenemia, immunoreactive fibrinogen levels are evaluated, obtaining results that show very low values that should be associated with prolonged clotting times. (1,2,7) Treatment in symptomatic individuals consists mainly of fibrinogen replacement therapy and strict daily follow-up of fibrinogen levels in plasma in order to ensure adequate hemostasis. (2,6) This is the report of an unusual hemorrhagic presentation (spontaneous vulvar hematoma) in an adult patient with a history of congenital hypofibrinogenemia.

CASE PRESENTATION

19-year-old female patient, from Bogotá (Colombia), housewife and of a low-income socioeconomic status household, with history

of congenital hypofibrinogenemia diagnosed during the neonatal period in a hemorrhagic context (without information on a specific event), compatible genetic study confirmed in anamnesis (not available in clinical history), without hemorrhagic manifestations subsequent to diagnosis nor pharmacological treatment. The young woman consulted the emergency department due to clinical symptoms of six hours of evolution and spontaneous appearance of expansive genital hematoma at the level of the right labium majus with hemorrhage associated with dissection of superficial tissues and altered state of consciousness. The physical examination showed hemodynamic instability and signs of low expenditure, presence of hematoma of approximately 20cm in diameter at the level of the right labium majus and active hemorrhage in its medial and inferior portion (Figure 1).

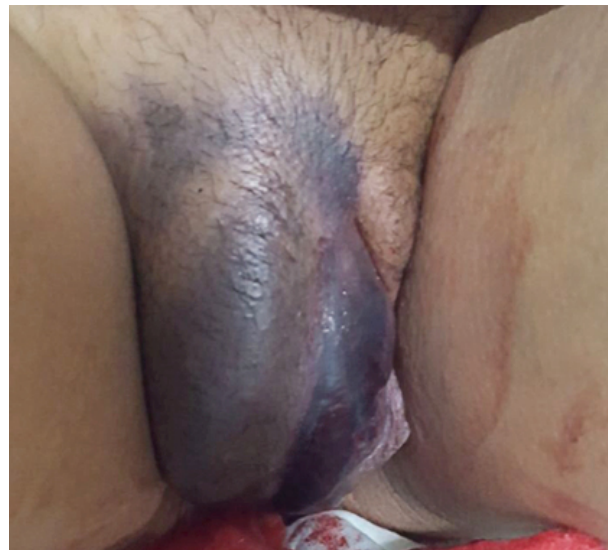

Figure 1. Vulvar hematoma at the level of the right labium majus with active inferomedial hemorrhage.

Source: Document obtained during the study.

A hypovolemic shock secondary to major hemorrhage was considered, for which Ringer's lactate infusion 3 000mL for 2 hours was prescribed, as well as intravenous tranexamic acid 1g and

compression at bleeding site. Laboratory tests on admission showed complete blood count with hemoglobin of 6.6 g/dL and no other alterations. Due to her history of hypofibrinogenemia, fibrinogen activity test was requested, which reported 74 mg/dL associated with prolonged clotting times (Table 1); based on the results, the patient received a transfusion of six units of cryoprecipitates and two units of packaged red blood cells.

The patient was assessed by the gynecology service, which considered the benefit of immediate surgical management. The hematoma was drained with intra-surgical size estimated at

17x7cm without complications. The hematology service assessed her again, confirming menstrual cycles without alterations and absence of family history of coagulopathies, bleeding or complications during invasive procedures (no surgical history) and episodes of involuntary pregnancy loss. In the immediate post-operative period, fibrinogen supplementation was initiated with doses adjusted according to weight; the dose were subsequently adjusted based on the fibrinogen values in plasma obtained every 8 hours, with an average daily dose of approximately 1.5 to 2 grams, administered for 8 days (Figure 2).

Table 1. Laboratory tests on admission.

Test	Value
Leukocytes	6 000 cell/uL
Neutrophils	5 260 cell/uL
Lymphocytes	570 cell/uL
Hemoglobin	6.6 g/dL
Hematocrit	21.3%
Mean corpuscular volume	82 fL
Mean corpuscular hemoglobin	25.5 pg
Platelets	159 000 cell
Partial thromboplastin time/day control	180/29 sec
Prothrombin time/day control	120/11.1 sec
Fibrinogen	74 mg/dL

Source: Own elaboration.

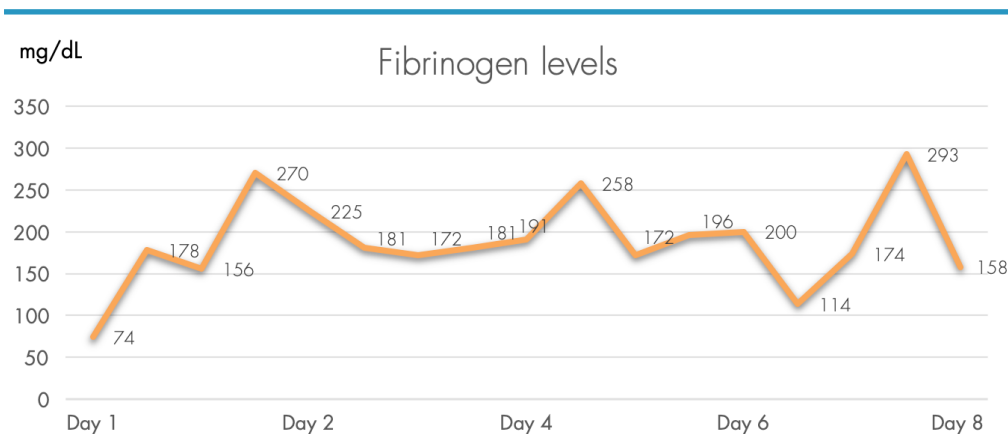


Figure 2. Fibrinogen values in plasma.

Source: Own elaboration.

The patient did not have any side effects to the administration of fibrinogen, and the treatment by intravenous administration was adequately tolerated without changes between doses until discharge from hospital.

DISCUSSION

Fibrinogen is a glycoprotein essential for hemostasis, and it is the soluble precursor of fibrin, which is required for clot formation; it also plays a key role on platelet aggregation and fibrinolysis. It is synthesized in the liver and circulates in plasma at concentrations of 2-4 g/L. (8-10)

Hypofibrinogenemia is a rare hematologic disorder that has no established incidence due to the absence of symptoms in most affected patients; it has a recessive inheritance pattern as does afibrinogenemia. In patients with hemorrhages of unknown etiology, studies should look for coagulation disorders. (1,2) The hereditary abnormalities of fibrinogen are divided into two: type 1 or quantitative, and type 2 or qualitative. (11)

The most frequent clinical manifestations of hypofibrinogenemia are umbilical cord hemorrhage, intracranial hemorrhage and mucosal hemorrhage; other less frequent manifestations are skeletal muscle hemorrhage, joint bleeds, paradoxical arterial and venous thrombotic events (9), ruptured spleen (3,12) and hepatic hematoma. (13) There are no reported cases describing spontaneous vulvar hematoma as a clinical manifestation.

For the case described here, the clinical history of the patient allowed guiding the diagnostic and treatment approach. However, it is important to highlight that an individual without a history of coagulopathy who presents unusual thrombotic or hemorrhagic events—which in some cases compromise life—must be a candidate for studies that include the evaluation of fibrinogen. More-

over, vulvar hematoma is a rare clinical finding in medicine, occurring mainly in obstetrics with an incidence of 1 to 2 per 1 000 births (14), and even more rare in non-obstetric population with an incidence of 3.7%. (15) Although in both cases it is usually associated with perineal trauma, vulvovaginal hematomas can rarely be triggered by spontaneous injury to a blood vessel or result from a hematological disorder. (16) In this case, a hematological disorder caused an expansive vulvar hematoma in a patient with a history of congenital fibrinogen disorder.

First-line treatment for a vulvovaginal hematoma is usually conservative, especially when the hematoma has a small to moderate size; however, if the hematoma has expansive behavior (16,17) or is >12cm, it is usually associated with decreased hematocrit, hemodynamic disorders, and transfusion requirement, suggesting the need for surgical management. Still, there is no clear scientific evidence to support this approach and the optimal timing for surgical management remains controversial.

On the other hand, it has been suggested that if the size of the hematoma is sufficient to trigger urological or neurological symptoms (16) or if its behavior is clearly expansive, surgical management should be urgent. (16,17) This was the approach determined for the patient described, achieving early hemostasis and stabilization, and avoiding complications derived from the procedure. Hemostasis can be achieved by ligation of the bleeding vessels, but another hematoma may occur as a complication, and in this context, embolization of the compromised blood vessels should be chosen as the second line of treatment. (17)

In the present case, transfusion of red blood cells concomitant to surgical management was necessary given the significant decrease in hemoglobin levels associated with hemodynamic instability.

The treatment of severe hemorrhages secondary to hypofibrinogenemia and afibrinogenemia is based on fibrinogen replacement, either with fresh frozen plasma, cryoprecipitate or concentrated fibrinogen, the latter being the treatment of choice due to its greater clinical safety. (8) Regarding fibrinogen concentrates replacement therapy as the mainstay of treatment for afibrinogenemia, it is recommended to individualize the clinical hemorrhagic context and the fibrinogen levels in plasma, aiming at a level not less than 75 mg/dL. (2,6,7) For the case described here, a dynamic dose of fibrinogen was indicated according to weight and with adjustment according to the plasmatic levels of fibrinogen evaluated every 8 hours during the entire hospital stay. This, along with surgical management and transfusion, allowed achieving a rapid and adequate clinical evolution, with discharge after 8 days of hospitalization without hemorrhagic recurrence, hemodynamic and hematological stability, and normal fibrinogen levels.

Given the impossibility of conducting large-scale studies on the treatment of fibrinogen disorders and their hemorrhagic manifestations, the best level of evidence available should be used for an early and appropriate approach; case reports are the main scientific contribution, and that is precisely the relevance of the information provided in this article.

The strengths of the current case report include the diagnostic and therapeutic approach of an unusual hemorrhagic presentation of hypofibrinogenemia that compromises life, highlighting the need, in this type of cases, for surgical management, transfusion and dynamic replacement of fibrinogen to prevent complications and seek the rapid improvement of the symptomatology. This is the first case of hypofibrinogenemia reported in Colombia, and the first in the world describing vulvar hema-

toma as a severe spontaneous hemorrhagic manifestation that compromises life.

The limitations of the study are the unavailability of the clinical history of the neonatal hemorrhagic event—which was useful to suspect the diagnosis—and the genetic studies carried out to confirm the diagnosis. Nevertheless, the lack of these data from the clinical history does not diminish the importance of what has been reported here, as this is the background anamnesis of the current clinical history described, with clarity and certainty, by the patient and her family, as is commonly observed during the evaluations made every day in the medical assistance field.

CONCLUSIONS

Afibrinogenemia is a rare disease that usually manifests itself with hemorrhagic events. Local control of such events includes supportive therapy, and fibrinogen replacement is the mainstay of therapy. It is important to suspect coagulation disorders in patients with bleeding at unusual sites, severe spontaneous bleeding, and unexpected thrombotic, obstetric, or adverse surgical events.

Having an adequate record of patients' clinical histories and their background information is essential to achieve a better diagnostic and therapeutic approach; in turn, this brings greater strength to the research and generates new knowledge, as all reported data could be relevant, this being one of the main lessons of the case report described here.

CONFLICT OF INTEREST

None stated by the authors.

FINANCING

None stated by the authors.

ACKNOWLEDGEMENTS

None stated by the authors.

REFERENCES

1. **Maghzal GJ, Brennan SO, Homer VM, George PM.** The molecular mechanisms of congenital hypofibrinogenemia. *Cell Mol Life Sci.* 2004;61(12):1427-38. <http://doi.org/c634z6>.
2. **de Moerloose P, Boehlen F, Neerman-Arbez M.** Fibrinogen and the Risk of Thrombosis. *Semin Thromb Hemost.* 2010;36(1):7-17. <http://doi.org/bp5vd2>.
3. **Arcagök BC, Özdemir N, Tekin A, Özcan R, Eliçevik M, Şenyüz OF, et al.** Spontaneous splenic rupture in a patient with congenital afibrinogenemia. *Turk Pediatr Ars.* 2014;49(3):247-9. <http://doi.org/c722>.
4. **Neerman-Arbez M, de Moerloose P.** Mutations in the fibrinogen gene cluster accounting for congenital afibrinogenemia: an update and report of 10 novel mutations. *Hum Mutat.* 2007;28(6):540-53. <http://doi.org/dh84px>.
5. **Ozdemir MA, Işık B, Patiroglu T, Karakukcu M, Mutlu FT, Yilmaz E, et al.** A case of congenital afibrinogenemia complicated with thromboembolic events that required repeated amputations. *Blood Coagul Fibrinolysis.* 2015;26(3):354-6. <http://doi.org/f662f7>.
6. **de Moerloose P, Neerman-Arbez M.** Congenital Fibrinogen Disorders. *Semin Thromb Hemost.* 2009;35(4):356-66. <http://doi.org/fh2v4t>.
7. **Korte W, Poon MC, Iorio A, Makris M.** Thrombosis in Inherited Fibrinogen Disorders. *Transfus Med Hemother.* 2017;44(2):70-6. <http://doi.org/f94xpi>.
8. **Peyvandi F.** Epidemiology and treatment of congenital fibrinogen deficiency. *Thromb Res.* 2012;130(Suppl 2):S7-11. <http://doi.org/f4pv5b>.
9. **Santoro C, Massaro F, Venosi S, Capria S, Baldacci E, Foà R, et al.** Severe Thrombotic Complications in Congenital Afibrinogenemia: A Pathophysiological and Management Dilemma. *Semin Thromb Hemost.* 2016;42(05):577-82. <http://doi.org/f8v9x9>.
10. **Stanciakova L, Kubisz P, Dobrotova M, Stasko J.** Congenital afibrinogenemia: from etiopathogenesis to challenging clinical management. *Expert Rev Hematol.* 2016;9(7):639-48. <http://doi.org/c723>.
11. **Neerman-Arbez M, De Moerloose P.** Hereditary Fibrinogen Abnormalities. Kaushansky K, Lichman MA, Prchal JT, Levi MM, Press OW, Burns LJ, et al, editors. *Williams Hematology.* 9th ed. McGraw-Hill; 2016 [cited 2018 May 19]. Available from: <https://bit.ly/2NAZSJd>.
12. **Taslimi R, Golshani K.** Thrombotic and hemorrhagic presentation of congenital hypo/afibrinogenemia. *Am J Emerg Med.* 2011;29(5):573.e3-573.e5. <http://doi.org/fcrkmv>.
13. **Malaquin S, Rebibo L, Chivot C, Badoux L, Mahjoub Y, Dupont H.** Congenital afibrinogenemia: a case report of a spontaneous hepatic hematoma. *Medicine (Baltimore).* 2016;95(28):e4150. <http://doi.org/c724>.
14. **Villella J, Garry D, Levine G, Glanz S, Figueroa R, Maulik D.** Postpartum angiographic embolization for vulvovaginal hematoma. A report of two cases. *J Reprod Med.* 2001 Jan [cited 2018 May 16];46(1):65-7. Available from: <https://bit.ly/2Jkv4IE>.
15. **Jones IS, O'Connor A.** Non-obstetric vulval trauma. *Emerg Med Australas.* 2013;25(1):36-9. <http://doi.org/c725>.
16. **Hong HR, Hwang KR, Kim SA, Kwon JE, Jeon HW, Choi JE, et al.** A case of vulvar hematoma with rupture of pseudoaneurysm of pudendal artery. *Obstet Gynecol Sci.* 2014;57(2):168-71. <http://doi.org/c726>.
17. **Takagi K, Akashi K, Horiuchi I, Nakamura E, Samejima K, Ushijima J, et al.** Managing vulvovaginal hematoma by arterial embolization as first-line hemostatic therapy. *Taiwan J Obstet Gynecol.* 2017;56(2):224-6. <http://doi.org/c727>.