



---

<https://doi.org/10.15446/cr.v6n2.84240>

## PHEOCHROMOCYTOMA PRESENTING AS FEVER OF UNKNOWN ORIGIN, A CASE REPORT

**Keywords:** Pheochromocytoma; Fever of Unknown Origin; Interleukin-6.  
**Palabras clave:** Feocromocitoma; Fiebre de origen desconocido; Interleucina-6.

---

Angélica María González-Clavijo

Juan David Muñoz-Loaiza

Jennifer Daniela Guzmán-Rojas

Johiner Jahir Vanegas-Antolinez

Laura Natalia Bermúdez-Silva

Universidad Nacional de Colombia

- Bogotá Campus - Faculty of Medicine -

Department of Physiological Sciences

- Bogotá D.C. - Colombia.

Luis Felipe Fierro-Maya

Instituto Nacional de Cancerología - Department

of Endocrinology - Bogotá D.C. - Colombia.

**Corresponding author**

Angélica María González-Clavijo.

Department of Physiological Sciences, Faculty of Medicine,

Universidad Nacional de Colombia.

Bogotá D.C. Colombia.

Email: amgonzalezc@unal.edu.co

## RESUMEN

**Introducción.** Un feocromocitoma es una neoplasia generalmente benigna de las células cromafines de la médula suprarrenal que se caracteriza por producir grandes cantidades de catecolaminas y que tiene la capacidad de secretar citoquinas como interleucina-1 IL-1, interleucina-6 IL-6 y factor de necrosis tumoral (TNF) alfa.

**Presentación del caso.** Paciente masculino de 24 años de edad, quien consultó por fiebre, mialgias y coluria. El sujeto presentó laboratorios compatibles con respuesta inflamatoria sistémica sin causa infecciosa o autoinmune y estudio de tomografía por emisión de positrones con fluorodesoxiglucosa que evidenció masa suprarrenal izquierda sin lesiones extra-adrenales. Al ingreso, los niveles de metanefrinas diferenciadas en orina y de cortisol basal se encontraban elevados; la hormona adrenocorticotropa (ACTH) no estaba suprimida, y el test de supresión de cortisol con dexametasona registró rango de hipercortisolismo. Se sospechó diagnóstico de feocromocitoma productor de catecolaminas y ACTH, por lo que se llevó a resección tumoral, con lo cual, llamativamente, se resolvieron todas las anomalías de respuesta inflamatoria. El reporte de patología confirmó un feocromocitoma, pero la inmunotinción para ACTH fue negativa. La revisión de la literatura y la comparación de los hallazgos con otros casos reportados permitieron inferir que se trató de un feocromocitoma productor de interleucinas.

**Conclusión.** El feocromocitoma puede ser una causa de síndrome febril, siendo la IL-6 el mediador principal que explicaría las manifestaciones de inflamación sistémica y el hipercortisolismo mediado por ACTH.

## ABSTRACT

**Introduction:** Pheochromocytoma is a generally benign neoplasm derived from chromaffin cells of the adrenal medulla. It is characterized by the production of large amounts of catecholamines and also by the capacity to secrete bioactive peptides such as cytokines, mainly interleukin-1 IL-1, interleukin-6 IL-6 and TNF alpha.

**Case presentation:** 24-year-old man, who consulted for fever, myalgia, and choluria. His laboratory tests were compatible with a systemic inflammatory response without infectious or autoimmune causes. However, a fluorodeoxyglucose positron emission tomography (FDG-PET) revealed a left adrenal mass, without extra-adrenal lesions. On admission, increased levels of differentiated urine methanephines, elevated baseline cortisol, non-suppressed adrenocorticotrophic hormone (ACTH), and positive low dose dexamethasone suppression test for cortisol were found. With suspicion of catecholamine and ACTH-producing pheochromocytoma, a tumor resection was performed, which conspicuously resolved all alterations of the inflammatory response. The histologic findings confirmed a pheochromocytoma, but the immunostaining for ACTH was negative. A literature review and the comparison of the findings with other reported cases allowed inferring that this was a case of interleukin-producing pheochromocytoma.

**Conclusion:** Pheochromocytoma may be a cause of febrile syndrome, with IL-6 being the main mediator, which explains the manifestations of systemic inflammation and ACTH-mediated hypercortisolism.

## INTRODUCTION

Fever of unknown origin (FUO) is a fever  $>38.3^{\circ}\text{C}$  that lasts for more than one week, whose cause cannot be established despite thorough investigations in the hospital. (1) There are over 200 causes of FUO, including infections, connective tissue diseases, and neoplasms. (2)

Generally, pheochromocytoma is a benign neoplasm derived from chromaffin cells of the adrenal medulla, with an estimated annual incidence of 0.5-0.8 cases per 100 000 people. (3) This type of tumor is characterized by the production of large amounts of catecholamines and also by the capacity to secrete bioactive peptides such as cytokines, mainly interleukin-1 IL-1, interleukin-6 IL-6, and TNF alpha.

IL-6 is an endogenous pyrogen that has the capacity to activate the hypothalamic-pituitary-adrenal axis at each of its central levels (4-7) and to stimulate the secretion of glucocorticoids directly in the adrenal cortex. This cytokine, together with IL-1, is the major inducer of hepatic acute phase protein synthesis. (8)

The following is the case of a patient with FUO, increased inflammatory markers, hypercortisolism secondary to excess production of adrenocorticotrophic hormone (ACTH) and an adrenal mass with histologic features of pheochromocytoma, in whom all symptoms normalized after tumor removal.

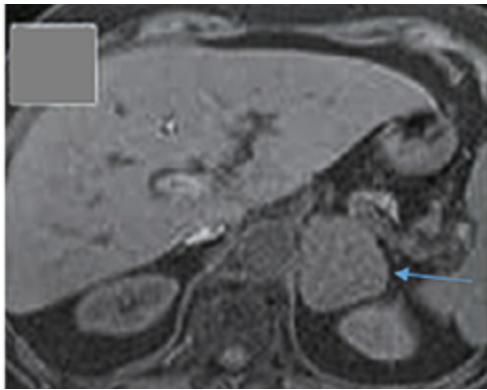
## CASE PRESENTATION

A 24-year-old male patient from Bogotá (Colombia), an industrial engineer, attended the emergency room of a private tertiary referral hospital for fever, most often  $>39^{\circ}\text{C}$ , for 10 days, accompanied by myalgia from the first day and choluria in the last 3 days. Although the feverish peaks had decreased with treatment with

non-steroidal anti-inflammatory drugs (NSAIDs) and acetaminophen, adequate control of this clinical sign had not been achieved.

The subject reported that two days before the onset of the fever, he visited a rural area with a warm climate (Melgar, Tolima). He had a history of smoking for 10 years until the year before the consultation, bicuspid aortic valve without hemodynamic consequences and appendectomy during childhood. With the exception of fever, his physical examination was normal; however, laboratory results showed marked elevation of leukocyte count (18 000 U/microliter, normal value 4 000-10 000) and platelet count (920 000 U/microliter, normal value up to 350 000), as well as increased liver transaminases ( $>500$  U/L, normal value up to 32) and C-reactive protein (5.5 mg/dL, normal value 0.0-0.8). According to serum creatinine and blood urea nitrogen values, kidney function was preserved.

In search of an infectious process, blood, stool and urine cultures for common germs and serology studies for dengue, leptospirosis, Epstein-Barr virus and cytomegalovirus were performed, which yielded negative results; therefore, infectious causes were ruled out. Subsequently, given the normal results of tests for antinuclear antibodies, antibodies to extractable nucleus antigens, and C3 and C4 complements, autoimmune causes were ruled out. Chest x-ray was normal and the echocardiogram reported no vegetations. A lumbar puncture was performed, after verification of a normal brain CT scan, which also had a normal result. However, an abdominal ultrasound showed a left adrenal mass that was described as a heterogeneous mass of 7x5cm, hypointense in T1, hyperintense in T2, with areas of necrosis and diffusion restriction, in an MRI of the abdomen with contrast agent (Figure 1).

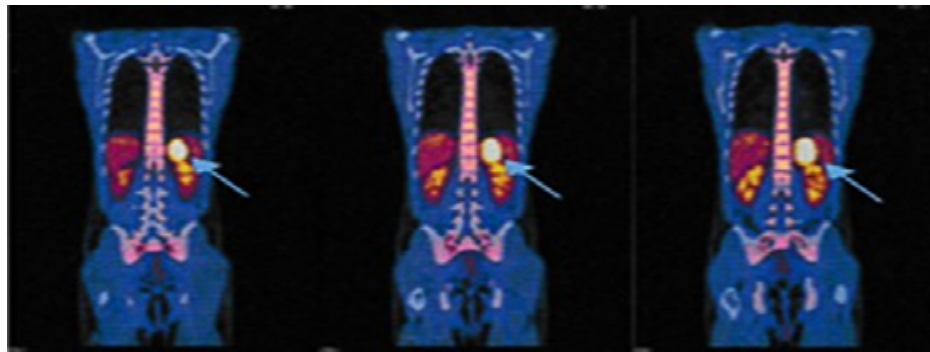


**Figure 1.** MRI of the abdomen (axial plane). The arrow points to the left adrenal mass of 7cm in diameter.

Source: Document obtained during the study.

At first, the fever was considered to be an incidentaloma but, since the fever persisted, tumor

fever was suspected. To rule out the presence of extra adrenal lesions, a fluorine-18-fluorodeoxyglucose positron emission tomography (FDG-PET) was performed, in which only the left adrenal mass with increased tracer uptake was evident (Figure 2). Moreover, the patient underwent high-performance liquid chromatography, which showed that 24-hour urinary metanephrine levels were elevated (7.8 ug/24 hours, normal value < 1.0). Morning ACTH and cortisol levels were 19 pg/mL (normal value 5-65 pg/mL) and 27 ug/dL (normal value 5-18 ug/dl), respectively; the latter was not suppressed in the overnight suppression test with 1 mg dexamethasone (22 ug/dL, normal value < 1.8U g/dL).



**Figure 2.** Fluorine-18-fluorodeoxyglucose positron emission tomography (coronal planes). The arrows indicate left adrenal mass with increased tracer uptake.

Source: Document obtained during the study.

Based on the findings, ACTH-producing pheochromocytoma was suspected, so the patient, after preoperative preparation with alpha-adrenergic blocking agents and intravascular repletion with isotonic fluids, was taken to surgery for open resection of the mass. During the procedure, the subject presented transient hypotension that was reverted with intravenous fluids. In the postoperative period, he did not require prolonged replacement glucocorticoid since baseline serum cortisol remained in normal ranges; he also had a rapid reversion of the

alterations and did not have more ever episodes. The pathology report confirmed pheochromocytoma with low Ki-67 proliferation index (1%), and immunohistochemistry was negative for ACTH and positive for chromogranin A and protein S100 in sustainable cells.

At the time of writing this case report, the patient had an adequate clinical progress, with no biochemical relapses and normal values of fractionated plasma metanephrine and urinary and plasma cortisol. The follow-up MRI of the abdomen did not show any structural relapse either.

Given the age of the patient and the increased PET-FDG uptake of the adrenal mass, it is likely that the pheochromocytoma found was associated with a mutation in the succinate dehydrogenase enzyme. However, this diagnosis was not confirmed because genetic testing could not be performed.

## DISCUSSION

Pheochromocytomas are tumors derived from chromaffin cells of the adrenal medulla, characterized by increased and uncontrolled secretion of catecholamines, (9) which can also produce other biologically active peptides such as IL-6.

This cytokine is a glycoprotein known primarily for its role in innate immune response due to its pyrogenic and acute-phase protein inducing capacity. (10)

In the central nervous system, IL-6 raises body temperature by stimulating the vascular organ of the lamina terminalis after binding to its IL-6R receptor, thus inducing the transcription of the cyclooxygenase-2 protein, a key enzyme for the production of prostaglandin E2 (PGE2). (11) The latter, through its EP3 receptor, is involved in the activation of various somatic and sympathetic thermogenic mechanisms responsible for fever in the preoptic nucleus neurons, (12) as described in Figure 3.

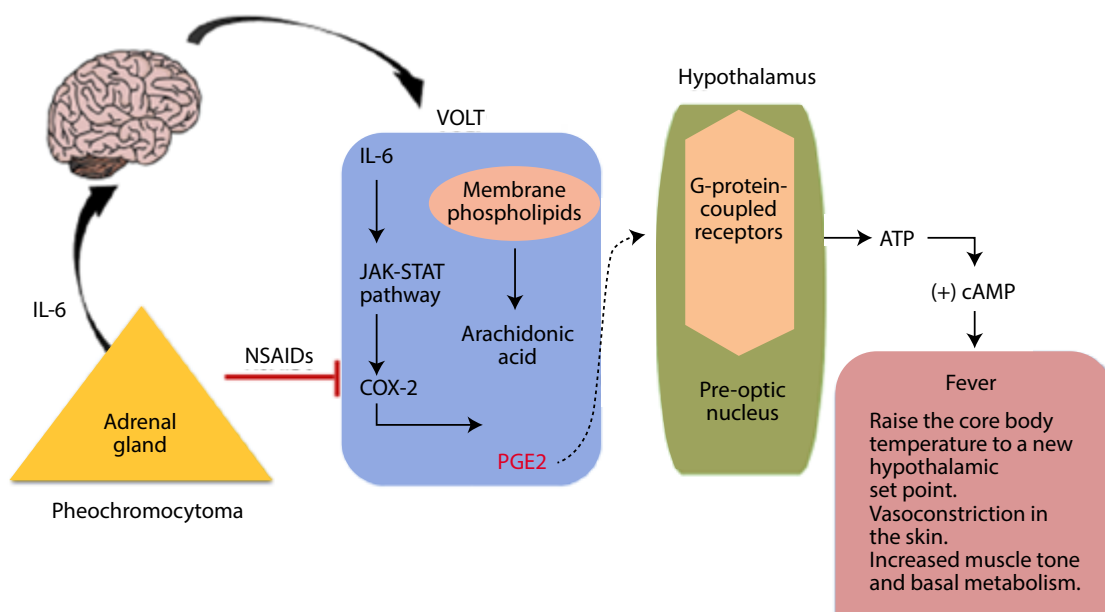


Figure 3. Mechanism of interleukin-6 fever production.

NSAIDs: non-steroidal anti-inflammatory drugs; VOLT: vascular organ of lamina terminalis; ATP: adenosine triphosphate; IL-6: interleukin-6; PGE2: prostaglandin E2; COX-2: cyclooxygenase 2; cAMP: cyclic adenosine monophosphate; JAK: Janus kinase; STAT: Signal transducer and activator of transcription proteins.

Source: Own elaboration.

IL-6 also stimulates the release of ACTH from the anterior pituitary gland; this hormone, in turn, promotes cortisol synthesis in the adrenal cortex. (13,14) The classic signaling

of this cytokine starts with the binding to its membrane receptor (IL-6R), which leads to the activation of the intracellular signaling pathway of the Janus kinases. Subsequently, signal

transduction-activated transcription factors translocate into the nucleus and gene expression is induced, as in the case of pro-opiomelanocortin (POMC), (15,16) which then generates ACTH by cleavage. In this way, it is possible to explain ACTH-dependent hypercortisolism, which was one of the biochemical alterations presented by the reported patient. It should be noted that, given the short time of evolution and the direct effect of IL-6 on corticotrophs, no suppression of the adrenal axis is expected when removing the IL-6 producing tumor, as in the reported case.

IL-6 hypersecretion also explains the changes in the leukocyte and platelet count, since it stimulates the differentiation of B and T lymphocytes (which causes leukocytosis) and intervenes in the proliferation and maturation of the megakaryocyte cell lines, generating thrombocytosis. In addition, it has proapoptotic effects on hepatocytes that generate hypertransaminasemia. (17,18)

In the case presented herein, the feverish peaks decreased after using NSAIDs, which act by blocking the production of PGE2. (19,20) However, complete remission of fever was only possible after surgery, which also allowed normalizing inflammatory markers (leukocytosis, thrombocytosis, hypoalbuminemia and hypertransaminasemia). This supports the role of IL-6 as responsible for the unusual manifestations observed in this case.

Although plasma levels could not be determined, the reversal of all inflammatory alterations after tumor removal and the review of similar clinical cases reported in the literature (21-28) allow us to infer that the secretion of IL-6 by a pheochromocytoma should be considered as an explanation of the fever and the marked inflammatory response (thrombocytosis, transaminasemia, and ACTH-dependent hypercortisolism).

## CONCLUSION

FUO is a condition with multiple causes, including tumors, which must be considered in the etiological diagnosis process. The presence of an IL-6 producing pheochromocytoma is a rather rare cause of FUO (less than 10 cases reported in the medical literature), so the description and publication of this report will allow clinicians to increase diagnostic suspicion and thus improve therapeutic interventions.

## ETHICAL CONSIDERATIONS

This article was prepared after obtaining the patient's informed consent to treat and disclose his medical history for scientific and academic purposes.

## CONFLICT OF INTEREST

None stated by the authors.

## FUNDING

None stated by the authors.

## ACKNOWLEDGEMENTS

None stated by the authors.

## REFERENCES

1. **Brown I, Finnigan NA.** Fever of Unknown Origin (FUO). In: StatPearls. Treasure Island: StatPearls Publishing; 2019.
2. **Kantorovich V, Pacak K.** Pheochromocytoma and paraganglioma. *Prog Brain Res.* 2010;182:343-73. <http://doi.org/cpwzpv>.
3. **Cunha BA, Lortholary O, Cunha CB.** Fever of unknown origin: a clinical approach. *Am. J. Med.* 2015;128(10):1138e1-1138e15. <http://doi.org/f3jbfm>.



4. **Zarkovic M, Ignjatovic S, Dajak M, Ciric J, Beleslin B, Savic S, et al.** Cortisol response to ACTH stimulation correlates with blood interleukin-6 concentration in healthy humans. *Eur J Endocrinol.* 2008;159(5):649-52. <http://doi.org/bvxpq4>.
5. **Navarra P, Tsagarakis S, Faria MS, Rees LH, Besser GM, Grossman AB.** Interleukins-1 and -6 stimulate the release of corticotropin-releasing hormone-41 from rat hypothalamus in vitro via the eicosanoid cyclooxygenase pathway. *Endocrinology.* 1991;128(1):37-44. <http://doi.org/dbd6cn>.
6. **Spinedi E, Hadid R, Daneva T, Gaillard RC.** Cytokines stimulate the CRH but not the vasopressin neuronal system: evidence for a median eminence site of interleukin-6 action. *Neuroendocrinology.* 1992;56(1):46-53. <http://doi.org/b4fshc>.
7. **Tsigos C, Papanicolaou DA, Defensor R, Mitsiadis CS, Kyrou I, Chrousos GP.** Dose effects of recombinant human interleukin-6 on pituitary hormone secretion and energy expenditure. *Neuroendocrinology.* 1997;66(1):54-62. <http://doi.org/c3b3fm>.
8. **Bethin KE, Vogt SK, Muglia LJ.** Interleukin-6 is an essential, corticotropin-releasing hormone-independent stimulator of the adrenal axis during immune system activation. *Proc Natl Acad Sci U S A.* 2000;97(16):9317-22. <http://doi.org/dw2hjf>.
9. **López-Calderón A, Calderón MD, Tresgüerras JAF.** Médula suprarrenal. In: Pombo M, Audí L, Bueno M, Calzada R, Cassorla F, Diéguez C, et al., editors. *Tratado de endocrinología pediátrica.* 4<sup>th</sup> ed. Barcelona: McGraw-Hill; 2019.
10. **Filella X, Molina R, Ballesta AM.** Estructura y función de las citocinas. *Med Integr.* 2003;39(2):63-71.
11. **Blomqvist A, Engblom D.** Neural Mechanisms of Inflammation-Induced Fever. *Neuroscientist.* 2018;24(4):381-99. <http://doi.org/gc7bmr>.
12. **Saavedra-Ramírez PG, Vásquez-Duque GM, González-Naranjo LA.** Interleucina-6: ¿amiga o enemiga? Bases para comprender su utilidad como objetivo terapéutico. *Iatreia.* 2011 [cited 2019 Oct 11];24(2):157-66. Available from: <https://bit.ly/380MDZ2>.
13. **Venihaki M, Dikkes P, Carrigan A, Karalis KP.** Corticotropin-releasing hormone regulates IL-6 expression during inflammation. *J. Clin. Invest.* 2001;108(8):1159-66. <http://doi.org/dqn8s2>.
14. **Contreras MG, Bonilla-Lara D, Pérez-Guerreo EE, Ruiz-Padilla AJ, Saucedo-Ulloa M, Saldaña-Angiano JM, et al.** Niveles altos de IL-6 asociados a efectos sistémicos y locales en la artritis reumatoide. *El Residente.* 2015;10(1):38-42.
15. **Melmed S, Jameson JL.** Hipófisis anterior: fisiología de las hormonas hipofisarias. In: Kasper D, Fauci A, Hauser S, Longo D, Jameson JL, Loscalzo J, editors. *Harrison. Principios de Medicina Interna.* 19<sup>th</sup> ed. New York: McGraw-Hill; 2019 [cited 2020 Jun 25]. Available from: <https://bit.ly/3dDCAdr>.
16. **Sokabe A, Mizooka M, Sakemi R, Kobayashi T, Kishikawa N, Yokobayashi K. et al.** Systemic Inflammatory Syndrome Associated with a Case of Jugular Paraganglioma. *Intern Med.* 2016;55(15):2105-8. <http://doi.org/f8xxtc>.
17. **Willenberg HS, Pärth G, Vögeli TA, Scherbaum WA, Bornstein SR.** Role of interleukin-6 in stress response in normal and tumorous adrenal cells and during chronic inflammation. *Ann N Y Acad Sci.* 2002;966:304-14. <http://doi.org/dnkcpt>.
18. **Toth B, Yokoyama Y, Schwacha MG, George RL, Rue LW, Bland KI, et al.** Insights into the role of interleukin-6 in the induction of hepatic injury after trauma-hemorrhagic shock. *J Appl Physiol.* (1985). 2004;97(6):2184-2189. <http://doi.org/b3fk6n>.
19. **Pérez-Guerra V, Ramírez-Cardona L, Yepes-Grajales OM, Vélez-Rivera JD, Marín-Zuluaga JI.** Falla hepática aguda sobre crónica. *Rev Col Gastroenterol.* 2016 [cited 2019 Oct 11];31(3):262-72. Available from: <https://bit.ly/2VjbEtn>.
20. **Vilalta NP, de Puig AC.** Gonadotropinas (LH y FSH) y corticotropina (ACTH). *Endocrinol Nutr.* 2007;54(2):109-17. <http://doi.org/b3qfzg>.
21. **Tokuda H, Hosoi T, Hayasaka K, Okamura K, Yoshimi N, Kozawa O.** Overexpression of protein kinase C-delta plays a crucial role in interleukin-6-producing pheochromocytoma presen-

- ting with acute inflammatory syndrome: a case report. *Horm Metab Res.* 2009;41(4):333-8. <http://doi.org/bn7zs4>.
22. Suzuki K, Miyashita A, Inoue Y, Iki S, Enomoto H, Takahashi Y, et al. Interleukin-6-Producing Pheochromocytoma. *Acta Haematol.* 1991;85(4):217-9. <http://doi.org/dbtjch>.
  23. Shimizu C, Kubo M, Takano K, Takano A, Kijima H, Saji H, et al. Interleukin-6 IL-6 producing pheochromocytoma: direct IL-6 suppression by non-steroidal anti-inflammatory drugs. *Clin Endocrinol (Oxf)*. 2001;54(3):405-10. <http://doi.org/bc4d7v>.
  24. Yarman S, Soyluk O, Altunoglu E, Tanakol R. Interleukin-6-producing pheochromocytoma presenting with fever of unknown origin. *Clinics (Sao Paulo)*. 2011;66(10):1843-5. <http://doi.org/dkps95>.
  25. Cheng X, Zhang M, Xiao Y, Li H, Zhang Y, Ji Z. Interleukin-6-producing pheochromocytoma as a new reason for fever of unknown origin: a retrospective study. *Endocr Pract.* 2018;24(6):507-511. <http://doi.org/d2f6>.
  26. Siddiqui UM, Matta S, Wessolossky MA, Haas R. Fever of Unknown Origin: Could It Be a Pheochromocytoma? A Case Report and Review of the Literature. *Case Rep Endocrinol.* 2018;2018:3792691. <http://doi.org/d2f8>.
  27. Minetto M, Dovio A, Ventura M, Cappia S, Daffar F, Terzolo M, et al. Interleukin-6 producing pheochromocytoma presenting with acute inflammatory syndrome. *J Endocrinol Invest.* 2003;26(5):453-7. <http://doi.org/d2f9>.
  28. Carvalho-Cunha N, Gomes L, Saraiva J, Paiva I. Interleukin-6 Producing Pheochromocytoma: A Rare Cause of Systemic Inflammatory Response Syndrome. *Case Rep Endocrinol.* 2019;2019:7906272. <http://doi.org/d2gb>.