



<https://doi.org/10.15446/cr.v6n1.81343>

HUMAN TAENIASIS INFECTION (*TAENIA SAGINATA*): A COMPLEX PUBLIC HEALTH PROBLEM. CASE REPORT

Keywords: Taeniasis; Praziquantel; Public Health.
Palabras clave: Teniasis; Praziquantel; Salud pública.

Shirley Natali Iza

Universidad Militar Nueva Granada
- Faculty of Medicine and Health Sciences -
Public Health Department
- Bogotá D.C. - Colombia.

José Alejandro Iza

Universidad Nacional de Colombia
- Bogotá Campus - Faculty of Medicine -
Public Health Department
- Bogotá D.C. - Colombia.

Julián Felipe Porras-Villamil

Universidad Nacional de Colombia
- Bogotá Campus - Faculty of Medicine -
Master's Degree in Infections and Tropical Health
- Bogotá D.C. - Colombia.

Mario Javier Olivera

Instituto Nacional de Salud
- Parasitology Group -
Bogotá D.C. - Colombia.

Corresponding author

Mario Javier Olivera. Parasitology Group,
Instituto Nacional de Salud. Bogotá D.C. Colombia.
Email: moliverajr@gmail.com.

ABSTRACT

Introduction: Taeniasis is a zoonosis that can be found worldwide. It is relatively easy to diagnose and its treatment is currently effective. This paper describes the follow-up of a case with persistent refractory taeniasis.

Case description: A 31-year-old female patient, street-food seller, was diagnosed with taeniasis when she was 21 years old. Since she was diagnosed, multiple treatments were administered, including albendazole, secnidazole, pirantel pamoate and several metronidazole schemes, which resulted in a partial improvement of the symptoms. In 2018, she expelled a parasite of ~1 meter in length, later described as *Taenia saginata*; praziquantel was prescribed, but it is not available in Colombia. The patient was referred to the Parasitology Service, and based on her medical history and a scientific review of literature, nitazoxanide (500mg, twice a day, for 3 days) and albendazole (400mg per day, for 3 days) were administered, eliminating the infection and improving the patient's quality of life.

Discussion: This case exposes two important clinical aspects. The first is the difficulty of monitoring and treating taeniasis cases. The second is the presence of persistent refractory taeniasis cases.

Conclusion: Secondary, tertiary and combination drugs are available for effective and safe treatment of taeniasis. However, there is a need to conduct further studies to achieve better diagnosis, prevention, education and control.

RESUMEN

Introducción. La teniasis es una zoonosis global con diagnóstico simple y tratamiento efectivo. A continuación se describe el seguimiento de un caso con teniasis refractaria persistente.

Presentación del caso. Paciente femenina de 31 años de edad y vendedora de comida callejera, quien fue diagnosticada con teniasis cuando tenía 21 años. Desde su diagnóstico, recibió múltiples regímenes terapéuticos (albendazol, secnidazol, pirantel pamoato y varios esquemas de metronidazol) que permitieron una mejoría parcial de los síntomas. En 2018, la paciente expulsó un parásito de ~1 m de longitud, después descrito como *Taenia saginata*, por lo que se indicó manejo con praziquantel, un medicamento no disponible en Colombia. La paciente fue referida al Servicio de Parasitología, y basados en su anamnesis y la revisión de literatura relevante, se indicó manejo con nitazoxanida (500mg, dos veces al día, por 3 días) y albendazol (400mg por día, por 3 días), con lo cual fue posible eliminar la infección.

Discusión. Este caso muestra dos aspectos clínicos importantes: la dificultad en el seguimiento y tratamiento de los casos de teniasis, y la presencia de casos de teniasis refractaria persistente.

Conclusión. Existen opciones de medicamentos secundarios, terciarios y la combinación de estos que son eficaces y seguros para tratar la teniasis. Sin embargo, es necesario hacer más estudios sobre su diagnóstico, prevención, educación y control.

INTRODUCTION

Helminths are multicellular, eukaryotic invertebrates that may have tube-like or flattened bodies. They are divided into two major groups: Nematohelminths and Platyhelminths. (1) The latter is subdivided into other subgroups, of which the most medically relevant is the Cestoda class with species such as: *Taenia solium*, *Taenia saginata*, *Taenia asiatica*, *Taenia multiceps*, *Hymenolepis nana*, *Diphyllobotrium latum* and species of *Echinococcus*. (2)

In general, human infection and disease, known as cestodiasis, is asymptomatic or has unspecific symptomatology. (2,3) However, some reported signs, symptoms and sequelae include weight loss, abdominal pain (4,5), distress secondary to observing proglottids in feces (6), expulsion of proglottids through the nose (7), decreased school performance, student dropout (8), pernicious anemia (3), gallbladder perforation (9), appendicitis (10) and bowel obstruction. (11) Moreover, the most important clinical aspect, and the greatest clinical burden, is derived from the consumption of *T. solium* eggs, which can cause the subsequent infection and aberrant encystment of the larval stage in various areas of the human body including muscles, eyes and central nervous system; the latter, especially in cases of neurocysticercosis, produces the largest associated morbidity. (12) Infections can be acquired in two general modes; the first one is secondary to the ingestion of cysts from badly prepared meat such as pork (*T. solium*, *T. asiatica*) or beef (*T. saginata*) (13), and the second is associated with the ingestion of *T. solium* eggs that can produce cysticercosis. (12)

Human taeniasis is one of the most important food-borne parasitic diseases, but it is preventable and treatable. (12) The Global Burden of Disease estimated that human cysticercosis by *T. solium* caused 503 000 disability-adjusted

life years (DALYs) (14), although extrapolations based on these estimations suggest that they can be as high as 2.7 million. (15) On the other hand, in Colombia, the National Survey of Intestinal Parasitism found a prevalence of taeniasis of 0.08% in children (7-10 years old). (16) Additionally, estimates in intestinal parasitism indicate that more than 800 million children require treatment for these parasites. (17)

Due to its association to poverty, lack of sanitation and poor hygienic practices, prevention includes good hygiene and improvement in sanitation, health education and life conditions. (17) A recent national study, which evaluated the residual incidence of taeniasis and cysticercosis through different methods, found that 3 626 cases were reported from 2009-2013, for a national crude rate of 7.7 cases per 100 000 inhabitants: 58.2% were males, 57% were over 40 years of age, and neurocysticercosis was found in 57.6% of the reported cases. (18)

Diagnosis relies upon direct microscopy of expelled eggs or proglottids in feces. In this context, parasite-specific secretory antigens can be used for detection (Copro-Ag). (12) Treatment includes: niclosamide (2 g/person as a single dose) (19), praziquantel (5–10 mg/kg as a single dose) (20), tribendimidine (200mg < 15 years or 400 mg per adult, single oral dose) (21), nitrozanide (15 mg/kg/day for 3 days or 1.2g in a single dose) (22) and albendazole (3×400 mg/person for 3 consecutive days). (23)

This paper presents a case of persistent taeniasis in a woman who reported having received multiple therapies without success, and aggravated by the fact that the primary therapy was not available in the country.

CASE REPORT

This is the case of a 31-year-old woman, mestizo, street-food seller, with incomplete high

school studies, born and currently living in Bogotá. She reported a clinical history of 10 years of evolution, consisting of abdominal pain associated with flatulence, alteration of intestinal behavior, irritability, bruxism, weight loss and expulsion of what she described as small parasites. In August 2018, parasitological diagnosis revealed *Taenia* spp. after finding proglottids in fecal samples; proglottids were described as *T. saginata* with 12 or more branches.

Direct wet mounts and formol-ether concentration technique were performed. Following the standard routine, proglottids were washed with distilled water, fixed in 10% neutral buffered formalin, and stored at room temperature until histological processing; then uterine branches were counted under a light microscope at a magnification of 40×. Upon examination, proglottids were found and later identified as *T. saginata* (Figures 1 and 2). Proglottid morphology was of approximately 11 mm in length and 8 mm wide, and the received segment had around 18 uterine branches. Eggs were roughly 33 micrometers in diameter.



Figure 1. Proglottid found in the patient feces. A) Proglottid of *Taenia saginata*; B) Proglottid of *Taenia saginata*.

Source: Image obtained while conducting the study.




Figure 2. Proglottid found in the patient's feces.

A) Proglottid of *Taenia saginata* 1X (stereoscope);

B) Proglottid of *Taenia saginata* 2x.

Source: Image obtained while conducting the study.

Her epidemiological history included the consumption of raw beef; the patient sells food in the street which has been prepared by her for several years. Physical examination revealed generalized mucocutaneous pallor, mild pain in the mesogastrium, presence of fragmented proglottids in the anus, and signs of excoriation in the perianal area. Laboratory blood exams showed only eosinophilia.

In spite of going repeatedly to medical consultation and having received multiple antiparasitic therapies —such as albendazole, secnidazole, pyrantel palmoate and several metronidazole schemes—, the symptomatology persisted. Due to the lack of improvement, she started to have alterations in her mood. In June 2017, she consulted for expulsion of an almost complete strobila (about 1 m long) without scolex, later identified as *T. saginata*; management with praziquantel was indicated, although it is not available in Colombia. Symptomatology persisted despite the expulsion of the parasite.

During the medical appointment, the treating physician reviewed the anamnesis, which revealed multiple antiparasitic schemes, made a scientific literature review and checked the national availability of medications considering that the patient continued describing the expulsion of proglottids. In August 2018, the

patient received an alternative treatment of nitazoxanide 500mg, twice a day, for 3 days in combination with albendazole 400mg per day, for 3 days. There were neither side effects nor abnormalities in laboratory parameters. After receiving this treatment, follow-up was performed at 1, 4, and 8 weeks in fecal samples to

look for proglottids and to check the presence, number, and viability of *Taenia* eggs. Successful treatment was achieved because the patient expelled the worms and the eggs were not found in subsequent control stool cultures. General recommendations for hygiene and adequate cooking of meats were given.

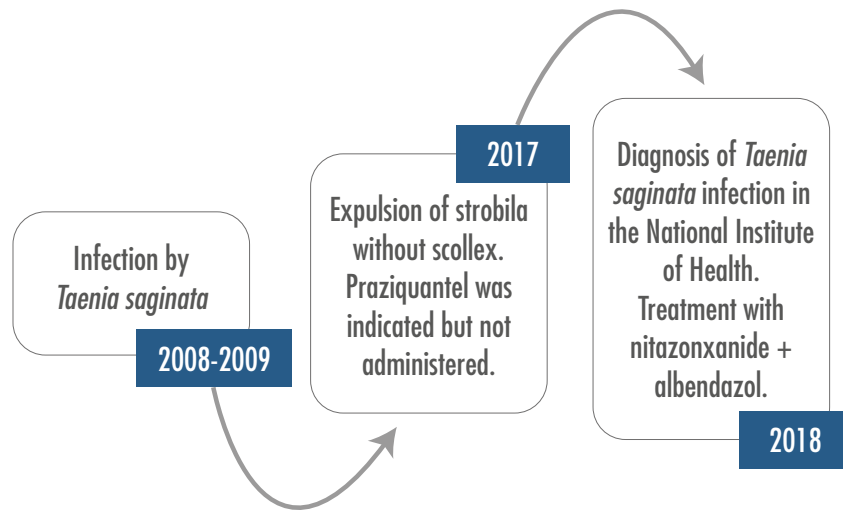


Figure 3. Timeline starting the year of possible infection, going through the diagnosis made by the National Institute of Health, and ending with the formulation of an effective and curative treatment. The patient's long clinical history is highlighted.

Source: Own elaboration.

DISCUSSION

This case report exposes two important clinical aspects. The first one is the difficulty of following and treating taeniasis in some cases. The second is the possibility of persistent or recurrent taeniasis in some people. This clinical situation can arise from two situations: 1) a possible increase in resistance to anti-parasitic drugs, and 2) the possibility of reinfection due to poor hygienic practices, which may be related to parasite species different from the one found in this patient. In this particular case, poor hygienic practices could have had dire consequences considering that the patient

serves and manipulates food; this means that she could have been the node of secondary and self-limited infections, thus revealing the importance of adequate personal and food manipulation habits.

As human taeniasis is a zoonotic threat, with significant global prevalence and a large and underestimated impact on economy, agriculture and public health (24), more studies are required to estimate its real burden. Nevertheless, some epidemiological studies estimate a prevalence of taeniasis in Latin America between 0.24% and 17.25%. (12) This prevalence tends to vary according to the population and its economic, infrastructure, education, culture and hygiene

conditions, as well as to the presence of farmed pigs and livestock. (12) Therefore, environmental health, animal health and human health must be addressed simultaneously, perhaps using the One Health approach. (25) In Colombia, specifically, one of the departments with the highest seroprevalence rates is Tolima, with an estimated prevalence of 17% for porcine cysticercosis and 43.4% for human taeniasis. (26) Likewise, seroprevalences as high as 40.19% have been estimated in other departments such as Vaupés, and others as low as 0.53% in Caldas. (27) It is worth mentioning that in Colombia no department is free of porcine cysticercosis due to poor livestock practices. (26)

The majority of patients with taeniasis do not present symptoms or pathognomonic findings; occasionally, they have slight abdominal discomfort or alterations of intestinal habits, as well as peripheral eosinophilia. *T. saginata* infection may present more symptoms, compared with other species, due to its larger size and length. (28) Even as this is the case, the importance of differentiation between species lies in warning and preventing the serious complications that *T. solium* can cause, such as neurocysticercosis. (12)

Regarding antiparasitic treatment, praziquantel 5-10 mg/kg or niclosamide 2g administered as a single dose, in association with the administration of a laxative, have become the drugs of choice. (13) These two drugs have shown effectiveness of 96% and 85%, respectively (29), and seem to be the most cost-effective treatments to manage taeniasis. (12) Praziquantel is, according to the literature, a better alternative than niclosamide in terms of cost, efficacy, availability and safety. (29) The literature reports only a few cases of unsuccessful treatment of *T. saginata* with praziquantel, although they have been effectively managed with nitazoxanide (30), which has shown to be effective and have a wide

spectrum of action against parasites resistant to other medications. (22,30,31) Despite of the available evidence, there are few studies in vivo, because they were approved by the FDA only until 2002. (30) Although nitazoxanide is not considered the drug of choice due to a higher prevalence of mild side effects compared to praziquantel (22,32), it is a viable alternative. (22,32) On the other hand, albendazole is also an alternative, especially with a dose of 400mg for 3 consecutive days in adults, obtaining a success rate close to 100%. (23) Unfortunately, in several countries of Central and South America, where this disease could be considered endemic (27), praziquantel and niclosamide are not available. (33)

In conclusion, this case draws attention to the great therapeutic support that is required to treat human taeniasis, as well as the alternatives for treatment when the drug of choice is not available. Other medications can be excellent alternatives for the community and the patient. However, there are still great challenges regarding prevention, education and control. The strengths of this case include the follow-up and adequate treatment of the patient, the literature search for therapeutic alternatives and the comprehensive clinical assessment of the patient. The weaknesses include the unavailability of the drug of choice and additional laboratory studies that could have contributed to better understanding this case.

CONCLUSION

This case draws attention to the difficulties in the follow-up and adequate treatment of patients with taeniasis. Furthermore it presents possible therapeutic alternatives when the drug of choice is not available. In terms of treatment solutions, multiple options of secondary, tertiary and combination drugs are available, which are effective and safe for treating taeniasis.

However, there is a need to increase diagnosis, prevention, education, control and treatment.

PATIENT'S PERSPECTIVE

The patient reports that she feels emotionally better and is hopeful that her symptoms will not recur. She says that she will follow the recommendations given to her, especially considering her work with food.

ETHICAL CONSIDERATIONS

Written informed consent was obtained for the publication of this case and the photographs obtained during the investigation.

TRANSPARENCY

The authors declare that all the information contained in this document is true, honest and transparent, that no important aspect of the case was omitted, and that every relevant characteristics or differences have been reported.

CONFLICT OF INTERESTS

None stated by the authors.

FUNDING

None stated by the authors.

ACKNOWLEDGMENT

None stated by the authors.

REFERENCES

1. **Ojha SC, Jaide C, Jinawath N, Rotjanapan P, Baral P.** Geohelminths: public health significance. *J Infect Dev Ctries.* 2014;8(1):5-16. <http://doi.org/dfmc>.
2. **Heyneman D.** Cestodes. In: Baron S, editor. *Medical Microbiology.* 4th ed. Galveston: University of Texas Medical Branch at Galveston; 1996 [cited 2019 Nov 22]. Available from: <https://bit.ly/2XFf3CU>.
3. **Webb C, Cabada MM.** Intestinal cestodes. *Curr Opin Infect Dis.* 2017;30(5):504-10. <http://doi.org/dfmd>.
4. **Tembo A, Craig PS.** *Taenia saginata* taeniosis: copro-antigen time-course in a voluntary self-infection. *J helminthol.* 2015;89(5):612-9. <http://doi.org/dfmf>.
5. **Palmer SR, Soulsby L, Torgerson P, Brown DWG.** *Oxford Textbook of Zoonoses: Biology, Clinical Practice, and Public Health Control.* 2nd ed. Oxford: Oxford University Press; 2011.
6. **García HH, González AE, Evans CA, Gilman RH.** *Taenia solium* cysticercosis. *Lancet.* 2003;362(9383):547-56. <http://doi.org/d5zfvn>.
7. **Prasada S, Bhat S, Vidyalakshmi K.** Taeniasis: An Unusual Presentation. *J Clin Diag Res.* 2017;11(6):DD03-4. <http://doi.org/dfmj>.
8. **Punina-Aguaguña SM.** La Parasitosis y su incidencia en el rendimiento escolar en los estudiantes del Octavo Año de Educación Básica del Instituto Tecnológico Pelileo, Año Lectivo 2008-2009. Ambato: Facultad de Ciencias Humanas y de la Educación, Universidad Técnica de Ambato; 2009 [cited 2019 Nov 22]. Available from: <https://bit.ly/2XB4yjV>.
9. **Hakeem SY, Rashid A, Khuroo S, Bali RS.** *Taenia saginata*: A Rare Cause of Gall Bladder Perforation. *Case Rep Surg.* 2012;2012:572484. <http://doi.org/gb7h4z>.
10. **Kulkarni AS, Joshi AR, Shere SK, Bindu RS.** Appendicular taeniasis presenting as acute appendicitis a report of two cases with review of literature. *Int J Health Sci Res.* 2014;4(4):194-7.
11. **Atef M, Emna T.** A rare cause of intestinal obstruction. *J Clin Case Rep.* 2015;5:594. <http://doi.org/dfmk>.
12. **Okello AL, Thomas LF.** Human taeniasis: current insights into prevention and management

- strategies in endemic countries. *Risk Manag Healthc Policy*. 2017;10:107-16. <http://doi.org/dfmm>.
13. **Symeonidou I, Arsenopoulos K, Tzilves D, Soba B, Gabriël S, Papadopoulos E.** Human taeniasis/cysticercosis: a potentially emerging parasitic disease in Europe. *Annals Gastroenter*. 2018;31(4):406-12. <http://doi.org/dfmn>.
 14. **Murray CJ, Vos T, Lozano R, Naghavi M, Flaxman AD, Michaud C, et al.** Disability-adjusted life years (DALYs) for 291 diseases and injuries in 21 regions, 1990-2010: a systematic analysis for the Global Burden of Disease Study 2010. *Lancet*. 2012;380(9859):2197-223. <http://doi.org/f2f8rw>.
 15. **Torgerson PR, Devleesschauwer B, Praet N, Speybroeck N, Willingham AL, Kasuga F, et al.** World Health Organization Estimates of the Global and Regional Disease Burden of 11 Foodborne Parasitic Diseases, 2010: A Data Synthesis. *PLoS Med*. 2015;12(12):e1001920. <http://doi.org/f8gr2f>.
 16. Ministerio de Salud y Protección Social. Encuesta nacional de parasitismo intestinal en población escolar Colombia, 2012-2014, Fase II. *Medellín: MinSalud; 2015*.
 17. World Health Organization (WHO). Intestinal worms: Epidemiology. New York: WHO. Available from: <https://bit.ly/37vA0oj>.
 18. **Rodríguez-Morales AJ, Yepes-Echeverri MC, Acevedo-Mendoza WF, Marín-Rincón HA, Culquichicón C, Parra-Valencia E, et al.** Mapping the residual incidence of taeniasis and cysticercosis in Colombia, 2009-2013, using geographical information systems: Implications for public health and travel medicine. *Travel Med Infect Dis*. 2018;22:51-7. <http://doi.org/gdk53z>.
 19. **Pearson RD, Hewlett EL.** Niclosamide therapy for tapeworm infections. *Annals Int Med*. 1985;102(4):550-1. <http://doi.org/dfmp>.
 20. **Pearson RD, Guerrant RL.** Praziquantel: a major advance in anthelmintic therapy. *Ann Intern Med*. 1983;99(2):195-8. <http://doi.org/dfmq>.
 21. **Steinmann P, Zhou XN, Du ZW, Jiang JY, Xiao SH, Wu ZX, et al.** Tribendimidine and albendazole for treating soil-transmitted helminths, *Strongyloides stercoralis* and *Taenia spp.*: open-label randomized trial. *PLoS Negl Trop Dis*. 2008;2(10):e322. <http://doi.org/db8cs2>.
 22. **Belkind-Valdovinos U, Belkind-Gerson J, Sánchez-Francia D, Espinoza-Ruiz MM, Lazcano-Ponce E.** Evaluación de la nitazoxanida en dosis única y por tres días en parasitosis intestinal. *Salud Pública Méx*. 2004;46(4):333-40.
 23. **Steinmann P, Utzinger J, Du ZW, Jiang JY, Chen JX, Hattendorf J, et al.** Efficacy of single-dose and triple-dose albendazole and mebendazole against soil-transmitted helminths and *Taenia spp.*: a randomized controlled trial. *PloS One*. 2011;6(9):e25003. <http://doi.org/fgz957>.
 24. **Braae UC, Thomas LF, Robertson LJ, Dermauw V, Dorny P, Willingham AL, et al.** Epidemiology of *Taenia saginata* taeniosis/cysticercosis: a systematic review of the distribution in the Americas. *Parasit Vectors*. 2018;11(1):518. <http://doi.org/dfmr>.
 25. **Fonseca AG, Torgal J, de Meneghi D, Gabriël S, Coelho AC, Vilhena M.** One Health-ness Evaluation of Cysticercosis Surveillance Design in Portugal. *Front Public Health*. 2018;6:74. <http://doi.org/gc865d>.
 26. **Giraldo-Forero JC, Riaño-Rodríguez MM, Vásquez-Arteaga LR.** Determinación de la seroprevalencia de cisticercosis porcina e identificación de teniasis humana en personas criadoras de cerdos en el área urbana del municipio de Coyaima, Tolima. *Revista Med*. 2017;25(1):31-45. <http://doi.org/dfms>.
 27. **Flórez-Sánchez AC, Pastrán SM, Vargas NS, Beltrán M, Enriquez Y, Peña AP, et al.** Cisticercosis en Colombia. Estudio de seroprevalencia 2008-2010. *Acta Neur Colomb*. 2013;29(2):73-86.
 28. **Mohanty A, Singh TS, Bhutia TO, Gupta P, Gupta P.** A case of albendazole and niclosamide resistant *Taenia saginata* infection. *J Res Med Sci*. 2017;5(6):2821. <http://doi.org/dfmt>.
 29. **Chai JY.** Praziquantel treatment in trematode and cestode infections: an update. *Infect Chemother*. 2013;45(1):32-43. <http://doi.org/dfmv>.

30. **Lateef M, Zargar SA, Khan AR, Nazir M, Shoukat A.** Successful treatment of niclosamide- and praziquantel-resistant beef tapeworm infection with nitazoxanide. *Int J Inf Diseases*. 2008;12(1):80-2. <http://doi.org/dcrcxh>.
31. **Speich B, Ame SM, Ali SM, Alles R, Hattendorf J, Utzinger J, et al.** Efficacy and Safety of Nitazoxanide, Albendazole, and Nitazoxanide-Albendazole against *Trichuris trichiura* Infection: A Randomized Controlled Trial. *PLoS Negl Trop Dis*. 2012;6(6):e1685. <http://doi.org/dfmw>.
32. **Belkind-Valdovinos U, Belkind-Gerson J, Sánchez-Francia D, Espinoza-Ruiz M, Lazcano-Ponce E.** Nitazoxanide vs albendazole against intestinal parasites in a single dose and for three days. *Salud Pública Méx*. 2004;46(4):333-40. <http://doi.org/c2dcz5>.
33. **Solano-Barquero A, León-Alán D.** Parasitosis debidas a helmintos intestinales: una actualización sobre su abordaje y tratamiento farmacológico en Costa Rica. *Rev Col Microb Quim Clin Costa Rica*. 2018;24(1):9-26.