

ORIGINAL RESEARCH

DOI:<http://dx.doi.org/10.15446/revfacmed.v62n4.45598>

Enamel defects in permanent first molars and incisors in individuals with cleft lip and/or palate

*Defectos de esmalte en primeros molares e incisivos en individuos con fisura labial y/o palatina*Vivian Patricia Saldias-Vargas¹ • Marcos Roberto Tovani-Palone¹ • Ana Paula Moura-Martins¹ • Gisele da Silva-Dalben¹ • Marcia Ribeiro-Gomide¹

Received: 16/09/2014 Accepted: 06/10/2014

¹ Hospital for Rehabilitation of Craniofacial Anomalies, University of São Paulo. Bauru, Brazil.

Correspondence: Marcos Roberto Tovani-Palone. Rua Silvio Marchione, 3-20, Vila Universitária 17012-900, Bauru (SP), Brazil. Telephone: (5514) 3235-8141. Fax: (5514) 3234-7818. E-mail: marcos_palone@hotmail.com.

[| Summary |](#)

Background. Enamel defects are common in deciduous and permanent maxillary incisors of individuals with lip and palate cleft, and their occurrence has been associated with the cleft, especially when the alveolus is affected.

Objective. To compare the prevalence of enamel defects in permanent maxillary and mandibular central incisors and first molars of individuals with cleft lip and palate, cleft palate, and without clefts.

Materials and methods. The study analyzed the case of 150 individuals —50 with cleft lip and palate, 50 with cleft palate and 50 without clefts—, of both genders and aged 6 to 12 years. The frequency, extent, and location of enamel alterations on the buccal aspect of teeth were evaluated by the modified DDE index.

Results. There was a greater manifestation of enamel defects in maxillary incisors and molars in groups with clefts, with statistically significant difference compared with the noncleft group.

Conclusions. The occurrence of enamel defects was common in permanent incisors and molars and was significantly associated with clefts.

Keywords: Cleft Lip; Cleft Palate; Incisor; Molar (MeSH).

Saldias-Vargas VP, Tovani-Palone MR, Moura-Martins AP, da Silva-Dalben G, Ribeiro-Gomide M. Enamel defects in permanent first molars and incisors in individuals with cleft lip and/or palate. Rev. Fac. Med. 2014;62(4):515-9. <http://dx.doi.org/10.15446/revfacmed.v62n4.45598>.

[Resumen](#)

Antecedentes. Los defectos de esmalte son comunes en los incisivos superiores deciduos y permanentes de individuos con fisura de labio y paladar; su ocurrencia ha sido asociada con la fisura, especialmente cuando el alveolo es afectado.

Objetivo. Comparar la prevalencia de defectos de esmalte en incisivos centrales y primeros molares superiores e inferiores permanentes de individuos con fisura labiopalatina, fisura palatina y sin fisura.

Materiales y métodos. El estudio analizó el caso de 150 individuos —50 con fisura labiopalatina, 50 con fisura palatina y 50 sin fisura— de ambos géneros entre 6 y 12 años. La frecuencia, extensión y localización de las alteraciones de esmalte en la superficie vestibular de los dientes fue evaluado por el índice DDE modificado.

Resultados. Hubo mayor manifestación de defectos de esmalte en incisivos y molares superiores en los grupos con fisuras, con diferencia estadística significativa comparada con el grupo sin fisura.

Conclusiones. La ocurrencia de defectos de esmalte fue común en incisivos y molares permanentes y estuvo significativamente asociada a las fisuras.

Palabras clave: Labio Leporino; Fisura del Paladar; Incisivo; Diente Molar (DeCS).

Saldias-Vargas VP, Tovani-Palone MR, Moura-Martins AP, da Silva-Dalben G, Ribeiro-Gomide M. Defectos de esmalte en primeros molares e incisivos en individuos con fisura labial y/o palatina. *Rev. Fac. Med.* 2014;62(4):515-9. <http://dx.doi.org/10.15446/revfacmed.v62n4.45598>.

Introduction

Enamel defects are common in deciduous and permanent maxillary incisors of individuals with cleft lip and palate, and their occurrence has been associated with the cleft, especially when the alveolus is affected. These defects may be classified according to their macroscopic appearance in two main categories: enamel hypoplasia and hypomineralized enamel. While hypoplasia is a quantitative defect, the hypomineralized enamel is a qualitative defect identified upon clinical examination as an abnormality in enamel translucency, also called opacity (1,2).

Even though enamel defects in maxillary incisors are widely investigated in children with clefts, other enamel alterations such as defects in permanent first molars combined with hypomineralized incisors (MIH) are not (1,3-5). In children without clefts, the prevalence of this disorder ranges from 2.8% to 40.2% (6-11). The studies reveal that the more the molars are affected, the higher the relative risk of opacities in incisors (1). In general, more than one permanent first molar is affected, and a typical characteristic of MIH is the asymmetric appearance (i.e. while the enamel of one molar is severely affected, the contralateral molar may be less or unaffected) (1,12).

From a clinical standpoint, MIH represents a serious problem for dental health due to the fast and unexpected development of caries during the eruption of the first molars, difficult re-anatomization of MIH, and the approach to be adopted when treatment is indicated. For the affected children, the experience of pain and sensitivity when the enamel is not intact discourages toothbrushing, and individuals also complain about the appearance of their incisors (13).

Thus, the main objective of this study was to compare the prevalence of enamel defects in permanent maxillary and mandibular central incisors and first molars of individuals with cleft lip and palate, cleft palate, and without clefts.

Materials and methods

The Institutional Review Board of the Hospital for Rehabilitation of Craniofacial Anomalies of the University of São Paulo (HRAC/USP) approved the study. Additionally, the parents or caretakers of the children signed an informed consent form agreeing to their participation in the study.

The sample consisted of three groups. Group I included 50 children with unilateral or bilateral complete cleft lip and palate (CLP) (19 females and 31 males). Group II comprised 50 children with cleft palate (CP), 22 females and 28 males, all attending the Pediatric Dentistry Clinic of HRAC/USP. Group III—the control group— included 50 children without clefts (NC), 33 females and 17 males, registered in a single public school in the city of Agudos, São Paulo, Brazil. The evaluation took 1,200 teeth and each tooth was divided in three thirds: incisal-occlusal, middle and cervical.

The inclusion criteria were Caucasoid children, aged 6 to 12 years, with erupted maxillary and mandibular central incisors and permanent first molars, with more than half of the crown exposed in the oral cavity, free of restorations, caries or orthodontic appliances. Individuals with clinical signs of white spot lesions caused by cervical demineralization in proximal and occlusal surfaces, as well as individuals with fluorosis ranging from yellow to dark brown, were symmetrically and bilaterally distributed, normally reaching several teeth.

Clinical examination was performed under artificial light using a dental mirror and dental probe. The buccal surfaces of maxillary and mandibular central incisors and first molars, as well as occlusal surfaces of maxillary and mandibular first molars, were examined after cleaning and drying with gauze to prevent the masking of defects by saliva or dental biofilm. All examinations were conducted by a single observer previously trained and submitted to an intra-rater test ($\kappa=1$).

Defects were classified according to the DDE index (14) in three categories: hypoplasia, demarcated opacities and diffuse opacities. Diffuse opacities presented with normal thickness of the affected enamel, translucence abnormalities, and undefined limits (Figure 1).

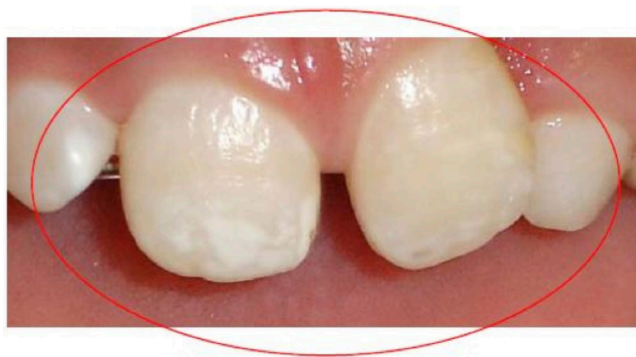

Figure 1. Diffuse opacity affecting the permanent maxillary incisors.

Demarcated opacities showed staining ranging from white, cream, yellow to brown bordered with the adjacent enamel (Figure 2).

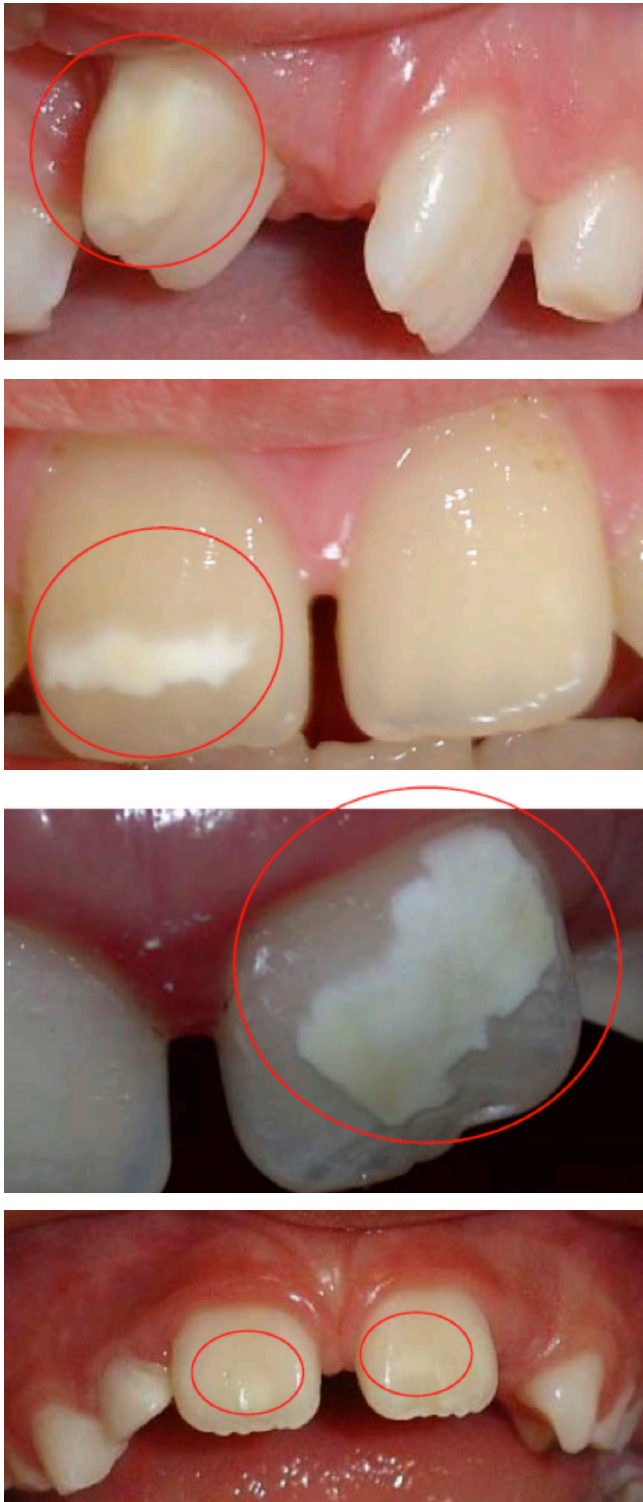

Figure 2. Demarcated opacities affecting the permanent maxillary incisors.

Hypoplasia was characterized by enamel thickness reduction, and the combination of defects was related to teeth showing the two defects, hypoplasia, and opacities in the same surface (Figure 3).

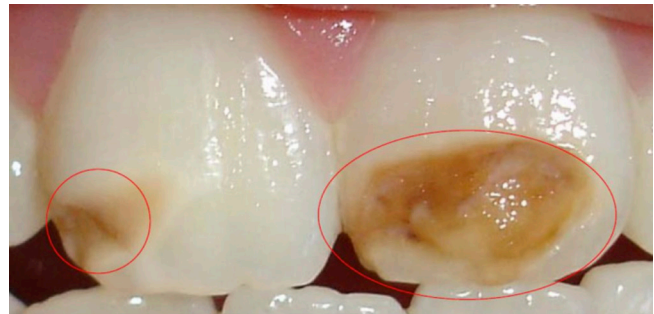

Figure 3. Enamel hypoplasia in permanent maxillary incisors.

The association between enamel defects and type of cleft was analyzed by the chi-square test ($\alpha=0.05$). Groups with and without clefts were compared, as well as groups with different types of clefts.

Results

For maxillary incisors, the cervical and middle thirds were the most affected in incisors on the cleft side. The incisal third was also affected, as well as incisal and middle thirds in the contralateral incisor in unilateral right and left cleft lip and palate, respectively. In the CP and NC groups, the incisal and middle thirds were the most affected. Both hypoplasia and opacities occurred more frequently in individuals with clefts, especially with alveolar involvement.

For mandibular incisors, there was a low occurrence of enamel defects in all groups, and opacity was the most common defect affecting the three thirds. There was only one case of hypoplasia in the NC group affecting the incisal third. Maxillary molars demonstrated marked occurrence of defects affecting all three thirds. Opacity was common for all groups with clefts ranging from 15% to 38%, affecting teeth related or not to the cleft. Hypoplasia was observed only in individuals with clefts. In the NC group only one case of opacity was observed, affecting the occlusal third.

In mandibular molars the occlusal and middle thirds were the most affected. Opacity was predominant in both molars, while hypoplasia was observed only in the mandibular right first molar. The prevalence of structural enamel defects considering at least one affected tooth was 12% for the NC group, 50% for the CP group and 94% for the CLP group. The prevalence of MIH, with at least one incisor and one molar

affected, was 4% for the NC group, 22% for the CP group, and 42% for the CLP group. Figure 4 shows the data on the prevalence of MIH defects.

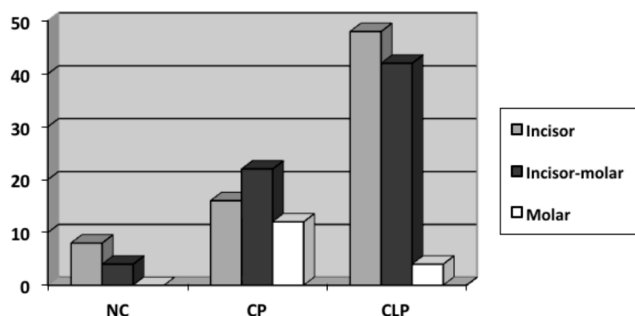


Figure 4. Prevalence of MIH defects in all studied groups.

There was a statistically significant association when groups with clefts were compared with the NC group, indicating that the anatomical defect of the cleft might influence the occurrence of MIH defects in the three studied groups (Table 1).

Table 1. Chi-square test for comparison of groups.

NCxCP	P= 0.21835471	P= 0.00744723	P= 0.01152199*
NCxCLP	P= 0.00000841*	P= 0.00000634*	P= 0.15312745
CPxCLP	P= 0.00060364*	P= 0.03205434*	P= 0.14036966

*Statistically significant; $p \leq 0.05$.

Note: NC: no clefts, CP: cleft palate, CLP: cleft lip and palate

When comparisons were applied only for groups with clefts, there was no statistically significant association for the molars. This fact could suggest that anterior teeth might be more likely to be affected by the MIH defects, possibly because of their proximity to the cleft, and also the severity of the defect.

Discussion

This study investigated enamel defects of central incisors and permanent first molars (MIH) in children with different types of clefts compared to individuals without clefts. A control group was included for better understanding of enamel defects, and to analyze the possible correlation with the different types of clefts.

The buccal surface was selected because of its susceptibility to enamel defects (15,16), with division in thirds to facilitate the report of the extent or severity of defects and assess the probable period when the injury occurred during formation of tooth enamel (17).

Involvement of the cervical and middle thirds by the different types of enamel defects was higher in incisors related to the cleft, yet the incisal third was also affected. This demonstrates the importance of the cleft region in the occurrence of dental structural defects, suggesting that rehabilitation procedures in early stages of life (18-21) may contribute to the occurrence of defects in the structure of developing teeth (22,23). Those results highlight the relationship of more severe clefts with dental defects in this region (24,25).

Involvement of the three thirds of maxillary molars and occlusal and middle surfaces of mandibular molars suggests that the damage, in lower proportion for the mandibular incisors, may have occurred throughout the period of tooth formation, comprising the first three years of life (1). It seems that there is no relationship between the type of defects and side of the cleft for maxillary molars because opacity was common for all groups with clefts, in percentages ranging from 15% to 38%, affecting teeth related or not to the cleft side. Hypoplasia was found only in individuals with clefts, supporting the hypothesis that dental development may be compromised by the cleft. For mandibular molars, opacity was the predominant defect. The structural defects of enamel in incisors, molars or both showed increasing prevalence in the NC, CP and CLP groups, which indicates that increasing the anatomic severity of the cleft causes a gradual increase in the defects, as well as in the severity of injuries.

So far, molecular biology studies (26,27) have not isolated specific genes related to the development of structural enamel defects. However, considering that odontogenesis occurs by epithelial-mesenchymal inductions, which present several regulatory genes that are repeatedly expressed in different stages of dental development, it may be inferred that any interference in these interactive sequential events might cause problems in tooth formation.

In conclusion, the findings strongly suggest that the cleft has an important role in the occurrence, distribution, and severity of enamel lesions, especially in maxillary permanent incisors and molars. Further investigations are needed to better understand the process of enamel development and the factors that interfere with this mechanism, thereby contributing to prevent the occurrence of MIH defects and their clinical consequences.

Conflict of Interest

None declared by the authors.

Financing

None declared by the authors.

Acknowledgements

None declared by the authors.

References

- Jälevik B.** Prevalence and diagnosis of Molar-Incisor-Hypomineralisation (MIH): a systematic review. *Eur Arch Paediatr Dent.* 2010;11:59-64.
- Suckling GW.** Developmental defects of enamel - historical and present-day perspectives of their pathogenesis. *Adv Dent Res.* 1989;3:87-94.
- Mathu-Muju K, Wright JT.** Diagnosis and treatment of molar incisor hypomineralization. *Compend Contin Educ Dent.* 2006;27:604-11.
- Tannure PN, Oliveira CAG, Maia LC, Vieira AR, Granjeiro JM, Costa MC.** Prevalence of dental anomalies in nonsyndromic individuals with cleft lip and palate: a systematic review and meta-analysis. *Cleft Palate Craniofac J.* 2012;49:194-200.
- Al Jamal GA, Hazza'a AM, Rawashdeh MA.** Prevalence of dental anomalies in a population of cleft lip and palate patients. *Cleft Palate Craniofac J.* 2010;47:413-20.
- Wuollet E, Laisi S, Salmela E, Ess A, Alaluusua S.** Background factors of molar-incisor hypomineralization in a group of Finnish children. *Acta Odontol Scand.* 2014;9:1-7.
- Ng JJ, Eu OC, Nair R, Hong CHL.** Prevalence of molar incisor hypomineralization (MIH) in Singaporean children. *Int J Paediatr Dent.* 2014 [Epub ahead of print]. Available from: <http://doi:10.1111/ipd.12100>.
- Petrou MA, Giraki M, Bissar AR, Basner R, Wempe C, Altarabulsi MB, et al.** Prevalence of Molar-Incisor-Hypomineralisation among school children in four German cities. *Int J Paediatr Dent.* 2013 [Epub ahead of print]. Available from: <http://doi:10.1111/ipd.12089>.
- Biondi AM, Cortese SG, Martínez K, Ortolani AM, Sebelli PM, Ienco M, et al.** Prevalence of molar incisor hypomineralization in the city of Buenos Aires. *Acta Odontol Latinoam.* 2011;24:81-5.
- Soviero V, Haubek D, Trindade C, Matta T, Poulsen S.** Prevalence and distribution of demarcated opacities and their sequelae in permanent 1st molars and incisors in 7 to 13-year-old Brazilian children. *Acta Odontol Scand.* 2009;67:170-5.
- Cho SY, Ki Y, Chu V.** Molar incisor hypomineralization in Hong Kong Chinese children. *Int J Paediatr Dent.* 2008;18:348-52.
- Weerheijm KL, Mejäre I.** Molar incisor hypomineralization: a questionnaire inventory of its occurrence in member countries of the European Academy of Paediatric Dentistry (EAPD). *Int J Paediatr Dent.* 2003;13:411-6.
- Alaluusua S.** Defining Developmental Enamel Defect-associated Childhood Caries Where Are We Now? *J Dent Res.* 2012;91:525-7.
- Suckling GW.** History of the DDE indices. *NZ Dent J.* 1998;94:9-11.
- Ruíz LA, Maya RR, D'Alpino PHP, Atta MT, Svizero NR.** Prevalence of enamel defects in permanent teeth of patients with complete cleft lip and palate. *Cleft Palate Craniofac J.* 2013;50:394-9.
- Hoffman RHS, Souza MLR, Cypriano S.** Prevalência de defeitos de esmalte e a sua relação com cárie dentária nas dentições decídua e permanente. *Cad Saude Publica.* 2007;23:435-44.
- Galante JMB.** Recorrência de alterações no esmalte nos incisivos centrais superiores de crianças com fissuras labiopalatinas [Online]. Bauru: Universidade de São Paulo, Hospital de Reabilitação de Anomalias Craniofaciais. 2007 [cited 2014 Aug 19]. Available from: <http://goo.gl/OYA3Ji>.
- Palone MRT.** Fatores modificadores da microbiota gastrointestinal e sua relação com malformações craniofaciais. *Rev Fac Ciênc Méd Sorocaba.* 2014;16:107-8.
- Palone MRT, Silva TR, Vieira NA, Dalben GS.** Microbiota do trato gastrointestinal de crianças com fissura envolvendo o palato. *Microbiol Foco.* 2013;5:11-8.
- Palone MRT, Silva TR, Vieira NA, Dalben GS.** Sequência de Robin e suas repercussões sobre a microbiota bucal: revisão de literatura. *Pediatr Mod.* 2013;49:445-50.
- Tovani Palone MR, Saldias Vargas VP.** Las fisuras labiopalatinas frente al equilibrio de la microbiota gastrointestinal. *Salud Cienc.* 2014;20:875-7.
- Carpentier S, Ghijselings E, Schoenaers J, Carels C, Verdonck A.** Enamel defects on the maxillary premolars in patients with cleft lip and/or palate: a retrospective case-control study. *Eur Arch Paediatr Dent.* 2014;15:159-65.
- Dixon DA.** Defects of structure and formation of the teeth in persons with cleft palate and the effect of reparative surgery on the dental tissues. *Oral Surg Oral Med Oral Pathol.* 1968;25:435-46.
- Camporesi M, Baccetti T, Marinelli A, Defraia E, Franchi L.** Maxillary dental anomalies in children with cleft lip and palate: a controlled study. *Int J Paediatr Dent.* 2010;20:442-50.
- Chapple JR, Nunn JH.** The oral health of children with clefts of the lip, palate, or both. *Cleft Palate Craniofac J.* 2001;38:525-8.
- Mitsiadis TA.** Development, Pathology and Regeneration of Dental and Orofacial Tissues: A Molecular Approach. *Mol Biol.* 2013;2:e107.
- Thesleff I.** The teeth. In: Ferretti P, Copp A, Tickle C, Moore G, editors. *Embryos genes and birth defects.* 2nd edition. John Wiley e Sons Ltd; 2006. pp. 515-35.