

CASE REPORT

DOI: <http://dx.doi.org/10.15446/revfacmed.v66n2.59798>

Acute abdomen and perforated duodenal ulcer in an adolescent: case report

Abdomen agudo quirúrgico, úlcera duodenal perforada en un adolescente: reporte de caso

Received: 30/08/2016. Accepted: 28/10/2016.

Luis Augusto Zarate-Suárez^{1,2} • Yinna Leonor Urquiza-Suárez^{1,2} • Carlos Felipe García^{1,2} • Diego Andrés Padilla-Mantilla^{1,2} • María Carolina Mendoza^{1,2}

¹ Fundación Oftalmológica de Santander - Clínica FOSCAL - Bucaramanga - Colombia.

² Universidad Autónoma de Bucaramanga - Faculty of Health Sciences - Department of Pediatric Surgery - Bucaramanga - Colombia.

Corresponding author: Yinna Leonor Urquiza-Suárez. Faculty of Health Sciences, Universidad Autónoma de Bucaramanga, Campus El Bosque. Calle 157 No. 19-55 (Cañaveral Parque). Telephone number: +57 7 6436111, ext.: 549-530. Floridablanca. Colombia. Email: medunab@unab.edu.co.

| Abstract |

Acute abdominal pain is one of the most frequent reasons for consultation in emergency departments. Its causes are diverse and are divided into surgical and medical. Surgical causes may be traumatic, obstructive or inflammatory. The last category includes perforated hollow viscus as a complication of duodenal ulcer, a rare condition in pediatrics.

This paper presents the case of a previously healthy 14-year-old adolescent who attended the emergency department due to the sudden onset and rapid progression of abdominal pain in the right hypochondrium, which radiated to the lower back on the same side. This condition was associated with vasovagal symptoms and was initially managed as urolithiasis, considering clinical deterioration and obvious signs of generalized peritonitis, which required a diagnostic laparoscopy followed by laparotomy by pediatric surgery.

Perforated duodenal ulcer was diagnosed during the procedure as the cause of the symptoms. This paper intends to show the experience of clinical cases with an initial diagnostic error and include complicated duodenal ulcer as a differential diagnosis.

Keywords: Acute Abdomen; Duodenal Ulcer; Pediatrics (MeSH).

Zarate-Suarez LA, Urquiza-Suárez YL, García CF, Padilla-Mantilla DA, Mendoza MC. Acute abdomen and perforated duodenal ulcer in an adolescent: case report. Rev. Fac. Med. 2018;66(2):279-281. English. doi: <http://dx.doi.org/10.15446/revfacmed.v66n2.59798>.

| Resumen |

El dolor abdominal agudo es uno de los principales motivos de consulta en los servicios de urgencias, sus causas son diversas y se dividen en quirúrgicas y médicas. En este artículo se hace mención a las causas quirúrgicas que pueden ser de tipo traumático, obstructivo o inflamatorio. En esta última categoría se encuentra la perforación de víscera hueca como complicación de úlcera duodenal, entidad poco frecuente en la edad pediátrica.

Se presenta el caso de un adolescente de 14 años, previamente sano, quien consultó a urgencias de medicina general por dolor abdominal de inicio súbito y de rápido progreso en hipocondrio derecho, con irradiación a zona lumbar del mismo lado, asociado a síntomas vaso vágales. Se da manejo primario como urolitiasis.

Ante el deterioro clínico y los signos evidentes de peritonitis generalizada, el paciente es llevado a laparoscopia diagnóstica que requiere conversión a laparotomía por cirugía pediátrica. El hallazgo quirúrgico es úlcera duodenal perforada como causa del cuadro clínico. Este reporte pretende mostrar la experiencia de los casos clínicos en los que se da un error diagnóstico inicial e incluir a la úlcera duodenal complicada como diagnóstico diferencial.

Palabras clave: Abdomen agudo; Úlcera duodenal; Pediatría (DeCS).

Zarate-Suarez LA, Urquiza-Suárez YL, García CF, Padilla-Mantilla DA, Mendoza MC. [Abdomen agudo quirúrgico, úlcera duodenal perforada en un adolescente: reporte de caso]. Rev. Fac. Med. 2018;66(2):279-281. English. doi: <http://dx.doi.org/10.15446/revfacmed.v66n2.59798>.

Introducción

Acute abdominal pain (AAP) is a frequent reason for consultation in pediatrics, is difficult to diagnose and constitutes a medical emergency. Semiologically, its onset may be sudden and insidious, and may progress rapidly or intermittently. It is associated with alterations in intestinal motility, oral intolerance and systemic symptoms such as fever.

The causes of AAP may be inflammatory, ischemic or obstructive, and include closed or penetrating abdominal trauma. Clinical diagnosis should be timely to avoid complications that endanger the patient's life, since incarcerated inguinal hernias and testicular and gynecological pathologies are entities that may present similar clinical characteristics of extra abdominal origin.

Clinical case

A 14-year-old adolescent with no relevant history attended the General Medicine Service due to abdominal pain of 20 minutes of evolution, of sudden onset and rapid progress, located in the hypochondrium and right iliac fossa, irradiated to the ipsilateral lumbar area, associated with emesis, diaphoresis and hypotension. Physical examination revealed mucocutaneous pallor, pain and abdominal guarding in right hemiabdomen with positive costovertebral angle tenderness.

Initially, medical management was directed to treat possible urolithiasis. Paraclinical examinations showed mild leukocytosis with neutrophilia, while abdominal ultrasound described anechoic free fluid in the right iliac fossa that did not rule out an appendiceal process. Renal etiology was ruled out.

The patient was assessed by pediatric surgery after eight hours due to persistent pain, generalized involuntary guarding and peritoneal irritation. A peptic ulcer was suggested and endoscopy of the upper digestive tract and H2 antihistamine were requested. An emergent surgery was performed considering the clinical deterioration of the patient, signs of shock and generalized peritonitis.

Management

A diagnostic laparoscopy was performed, obtaining the following findings: seropurulent fluid with duodenal and biliary content of 100cc, perforation on the anterior wall of the pyloric region of about 0.8cm in diameter (Figure 1), localized serositis, edema and fibrin. Due to technical difficulties, the procedure was converted to mid-supraumbilical laparotomy, and diuresis by planes until the cavity, revision of the entire duodenum, perforation raffia with absorbable suture (vicryl 3) omentum patch, cavity washing and cleaning, synthesis by planes with absorbable suture (vicryl) 0 and skin with PDS 4.0 were performed without complications.

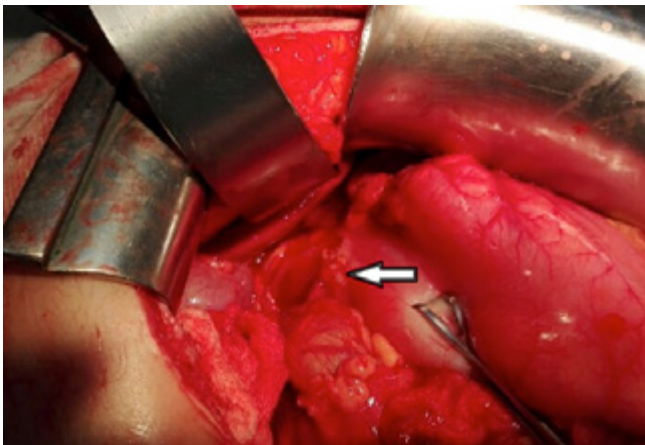


Figure 1. Intraoperative: Perforated duodenal ulcer on the anterior wall of the pyloric region.

Source: Own elaboration based on data obtained during the study.

Follow-up

The patient was transferred to the intensive care unit with proton pump inhibitor and antibiotics. After five days, intestinal restitution began and discharge was indicated without complications after eight days.

One month after discharge, an endoscopy of the digestive tract with biopsy was performed confirming the presence of *Helicobacter pylori*. Eradication treatment was indicated according to the guidelines established by the Colombian Society of Gastroenterology.

Discussion

AAP in pediatrics is a syndrome constituted by different pathologies that require timely diagnosis and emergent surgery for proper management. (1,2) This entity occurs between 5-15% of patients aged 5 to 15 years. (3) Clinical diagnosis is not easy to achieve, thus becoming a challenge for general practitioners in emergency services. Clinical manifestations are unclear and diagnostic aids are sometimes inconclusive or unspecific. (4) This situation causes a high percentage of diagnostic errors and masks abdominal surgical processes, as in the case of this patient, who was treated with complete analgesia because the first diagnostic impression was urolithiasis. The way to approach a child or adolescent and their family allows learning about the onset of symptoms and guide the diagnosis; in consequence, developing an adequate clinical history and a good physical examination is highly important. (5)

Bearing in mind that surgical abdominal pain may be caused by multiple causes, and that such causes vary according with pediatric age distribution, allows obtaining differential diagnoses to make relevant decisions (6,7) (Table 1).

The most frequent infectious cause in Colombia, according to the Colombian Society of Pediatrics, is acute appendicitis, prevalent in 25 cases per 10 000 school children and adolescents. (8,9) Traumatic causes are considered of great importance due to the increase in the last decades of child abuse and accident rates in the country. (10) In turn, obstructive causes are frequent in toddlers and preschool infants, as well as poor rotation, intussusception, Meckel's diverticulum and bowel volvulus, among others. (11)

Table 1. Distribution of AAP causes according to age ranges in pediatrics.

Neonates to preschoolers	Preschoolers to school children	Adolescents
Incarcerated inguinal hernia	Acute appendicitis	Acute appendicitis
Intussusception	Trauma	Pancreatitis
Bowel volvulus	Bowel obstruction by adhesion	Complicated duodenal ulcer
Intestinal malrotation	Parasitosis	Cholecystitis
Complicated Meckel's diverticulum	Neoplasms	Acalculous cholecystitis
Congenital anomalies	Testicular torsion	Bowel obstruction by adhesion
Trauma	Ovarian torsion	Trauma
		Ovarian torsion

Source: Own elaboration based on Reust & Williams. (9)

The initial approach to a patient with acute abdominal pain should begin with a general assessment of the child, including appearance, food intake, diuresis and level of activity, through eye contact or interviewing a relative. Special attention should be paid to abdominal pain history, which should include associated symptoms, previous episodes of abdominal pain, and pain intensity. Some of the clinical manifestations that lead to suspect AAP are absence of bowel sounds, bilious vomiting, involuntary abdominal guarding, rebound tenderness, abdominal rigidity and fever, when it appears after the onset of abdominal pain and emesis. Acute chronic intermittent abdominal pain is less likely to be related to a surgical cause than to a first episode of acute pain. (9)

Duodenal peptic ulcer (DPU) is relatively rare in pediatrics. In Colombia, an incidence rate of 4.4 per 10 000 children has been reported. (12) It is classified into primary and secondary; primary ulcers present along with infection by *H. pylori*, bacteria related to socioeconomic conditions and found in 2/3 of the world population, in 80% of the adults of developing countries. (13,14) In Japan, a 20-year follow-up study was conducted with a sample of 52 patients, of whom 90% were adolescents with acute abdominal pain, predominantly

male, with family risk factors for DPU such as smoking, alcohol consumption, use of chronic drugs, and in all cases *H. pylori* infection was identified as the main cause. (15)

Secondary ulcers are related to causes such as burns, exogenous drugs (NSAIDs or steroids), stress, hypergastrinemia, causes of central origin due to trauma or neoplasms, low weight and prematurity in neonates, and gastrin hypersecretion of parietal cells due to maternal or spontaneous influence. The latter has been reported in isolation in these age ranges. (16,17)

It should be borne in mind that other ulcers may be silent until they manifest as a perforation with shock in patients with acute abdomen, since laparotomy is the only diagnosis method of this disease, as in the case presented here. (18,19)

Conclusions

Complicated duodenal peptic ulcer should be considered in differential diagnoses of acute surgical abdomen in children and adolescents. In Colombia, a developing country with a high rate of *H. pylori* infection, its existence is well documented except for pediatrics. For this reason, it is important to promote prevalence studies in the Colombian population that allow developing eradication protocols to avoid complications.

Conflicts of interest

None stated by the authors.

Funding

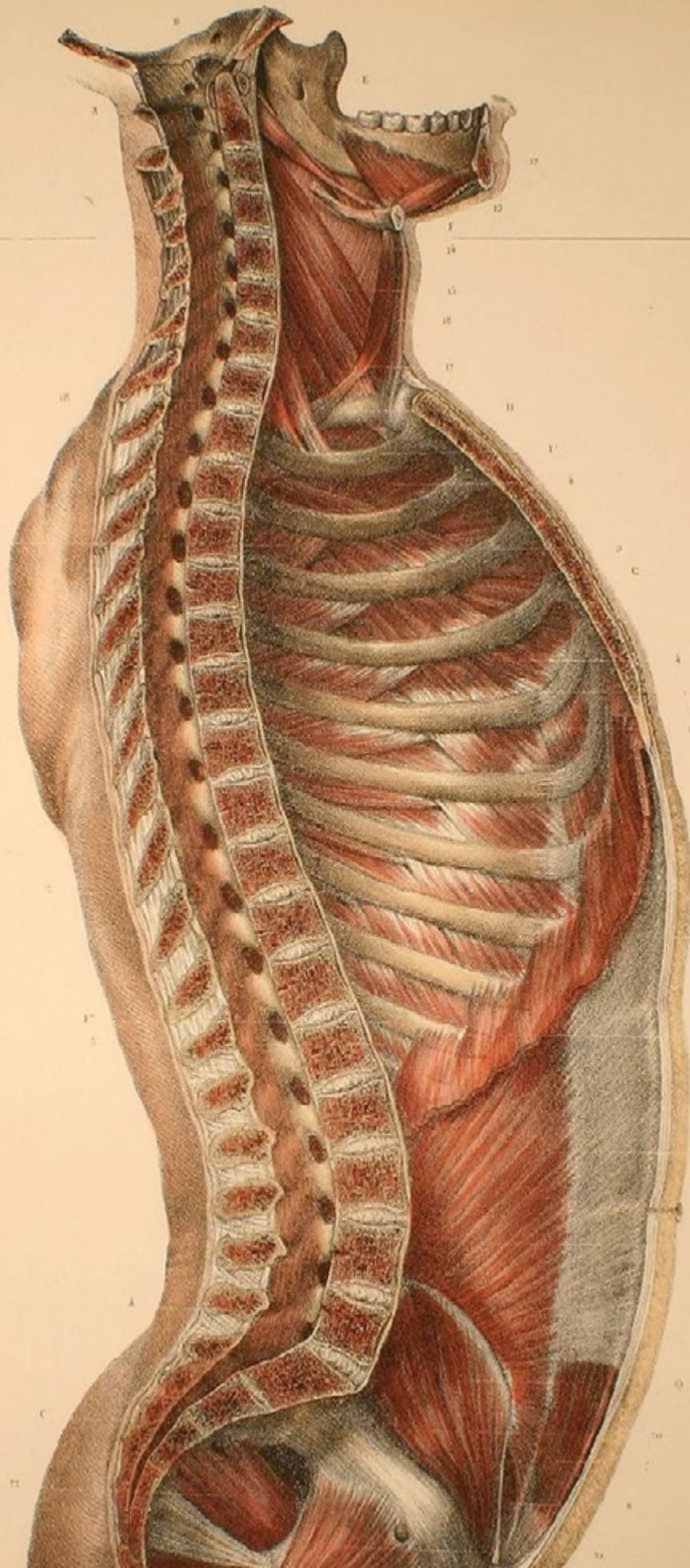
None stated by the authors.

Acknowledgement

None stated by the authors.

References

- Morrow S, Newman K.** Current management of appendicitis. *Semin. Pediatr. Surg.* 2007;16(1):34-40. <http://doi.org/bcbjrt>.
- Tamayo-Meneses L, Castillo-Loayza J.** Dolor abdominal agudo, síntoma indirecto de neumonía: a propósito de tres casos. *Cuad. Hosp. Clín.* 2006 [cited 2016 Oct 19];51(1):65-70. Available from: <https://goo.gl/FY43vC>.
- Árdela E, Domínguez F, Ansó S, Arce J.** Dolor abdominal en la edad escolar: Avances. *Bol. Pediatría.* 2000;40(173):147-157.
- Lin WC, Lin CH.** Multidetector computed tomography in the evaluation of pediatric acute abdominal pain in the emergency department. *Biomedicine (Taipei).* 2016;6(2):10. <http://doi.org/cfpz>.
- Nakayama DK.** Examination of the Acute Abdomen in Children. *J. Surg. Educ.* 2016;73(3):548-52. <http://doi.org/f8k3qx>.
- Coca-Robinot D, Liébana de Rojas C, Aguirre-Pascual E.** Abdominal emergencies in pediatrics. *Radiología.* 2016;58(Suppl 2):80-91. <http://doi.org/cfp2>.
- García-Aparicio J.** Abdomen agudo en el niño. *Protocolos diagnóstico-terapéuticos de Urgencias Pediátricas SEUP-AEP.* Madrid: Hospital Infantil Universitario La Paz. Available from: <https://goo.gl/5ZMQhB>.
- Holguín D, Bautista, F, Fierro F, Holguín D, Rojas A.** Prevalencia del dolor abdominal agudo y sus manifestaciones en el paciente pediátrico. *Pediatría.* 2011;44(1).
- Reust CE, Williams A.** Acute Abdominal Pain in Children. *Am. Fam. Physician.* 2016;93(10):830-6.
- Gomes de Souza P, Ferreira AL.** Acute abdominal pain as a manifestation of physical violence in an infant: alert to pediatricians. *Rev. Paul. Pediatr.* 2012;30(4):608-12. <http://doi.org/cjxh>.
- Mazzi E.** Dolor abdominal en niños. *Rev. Soc. Bol. Ped.* 2013 [cited 2016 Oct 19];52(1):50-7. Available from: <https://goo.gl/RRT6QM>.
- Uribe-Garay C.** Enfermedad ácido-péptica. *CCAP.* 2014 [cited 2018 Jan 29];13(3):37-48. Available from: <https://goo.gl/wkVogA>.
- Malaty HM.** Epidemiology of Helicobacter pylori. *Best. Pract. Res. Clin. Gastroenterol.* 2007;21:205-14. <http://doi.org/bb7xdt>.
- Suebaum S, Michetti P.** Helicobacter pylori infection. *N. Engl. J. Med.* 2002;347:1175-86. <http://doi.org/dq2t6t>.
- Hua MC, Kong MS, Lai MW, Luo CC.** Perforated peptic ulcer in children: a 20-year experience. *J. Pediatr. Gastroenterol. Nutr.* 2007;45(1):71-4. <http://doi.org/fq84jj>.
- Amoei A, Ehsani F, Zarch MB, Tabatabaei SM, Ghodrati-pour Z.** Peritonitis Following Duodenal Ulcer Perforation in a Newborn: A Case Report. *J. Clin. Diagn. Res.* 2016;10(11):PD10-PD11. <http://doi.org/cfp3>.
- Trujillo M, García R, Sagaró E, Frago T, Lazo O, Borbolla E, et al.** Úlceras gastroduodenal en pediatría. *Rev. Gastroenterol. Perú.* 1997;17(2).
- Yildiz T, Ilce HT, Ceran C, Ilce Z.** Simple patch closure for perforated peptic ulcer in children followed by Helicobacter pylori eradication. *Pak. J. Med. Sci.* 2014;30(3):493-496. <http://doi.org/cfp4>.
- Yadav SK, Gupta V, El Kohly A, Al Fadhli W.** Perforated duodenal ulcer: A rare complication of deferaxirox in children. *Indian. J. Pharmacol.* 2013;45(3):293. <http://doi.org/cfp5>.



JEAN MARC BOURGERY
"Traité complet de l'anatomie de l'homme"
PARIS 1832-1854